

1980.04

TECHNION - ISRAEL INSTITUTE OF TECHNOLOGY
TECHNION RESEARCH & DEVELOPMENT FOUNDATION

THE JULIUS SILVER INSTITUTE OF
BIO-MEDICAL ENGINEERING SCIENCES

EXAMINATION OF THE CRANIAL RHYTHM
IN LONG-STANDING COMA
AND CHRONIC NEUROLOGIC CASES

Z. Karni, J.E. Upledger, J. Mizrahi, L. Heller,
E. Becker and T. Najenson

TSI 04-80

April 1980

Introduction

In an earlier report⁽¹⁾, a case of a child who had cranially been treated by Dr. J.E. Upledger, F.A.A.O, Assoc. Professor at the Biomechanics Department, College of Osteopathic Medicine, Michigan State University, Michigan, USA, and a Visiting Professor at the Department of Biomedical Engineering, Technion - Israel Institute of Technology, during his recent summer visit to this country, was described. Here the results of a cranial examination performed by Dr. Upledger on patients at the intensive care units of the Loewenstein Rehabilitation Hospital, Ra'anana, are reported.

The purpose of the examination was to establish whether or not these patients, some of them in coma for months and years, still possess a cranial rhythm and if the rhythm is substantially retarded in both amplitude and frequency in comparison with the normal values. The cranial rhythm was evaluated by Dr. Upledger by the light palpation of the cranium or the extremities and the frequency counted in cycles per minutes (cpm). Later, however, in some of the cases, a strain-plethysmographic measurement⁽²⁾ was carried out which checked very nicely with the values called for those patients.

In the following, the results of the examination along with a brief description of the various cases are presented. It is, however, preceded by a short account of the nature of the cranial rhythm and the role it plays as the principal cue which directs the physician in and during the cranial treatment.

The Cranial Rhythm

The cranial content - nerves, arteries and veins, soft tissue, membranes etc. - is in a fluid state within the enclosing membrane of the dura mater. The inner structure is compartmental^(3,4) and shell like, divided into several layers. Beneath the dura mater is the subdural space bounded below by the arachnoid membrane which runs almost parallel to the dura. Further down is the subarchnoidal space between the membranes of the arachnoid and the pia mater, the latter covering the cerebral cortex. In the subarachnoidal space flows the cerebrospinal fluid (CSF) and the subpial space contains the interstitial fluid - that extracellular fluid outside and between the nerve cells. The fluid structure is, therefore, primarily bi-phasic with the more viscous and quasi stationary interstitial fluid as the inner core which is circulated from the outside by the lighter, almost inviscid CSF.

The hydraulic content is subjected to the pulsatory motions of the arterial system, the venous system and also to the pulmonary system which transmits its effect to the dura mater through the vertebral connections along the cervical section of the spinal column. The lateral displacements which all these systems induce upon the fluid region sets the latter into motion, the nature of which depends on its material properties and on the mechanical behavior of the container^(5,6).

The classical Monro -Kellie theory^(7,8) considered the container - namely the skull bones - rigid, and the inner fluid - incompressible. The immediate implication of these assumptions was that in the event of any induced displacements the only way for the fluid to give way was by a rigid displacement to another compartment of the body so that the total volume remained intact. This seemed unlikely, however, the Monro -Kellie doctrine prevailed, at least as a first approximation,

for quite a while.

The incompressibility assumption was later relaxed; the fluid was assumed compressible and measurements were made to find the gross bulk modulus of the entire fluid⁽⁹⁾ and the moduli of each of its phases, namely that of the CSF and of the interstitial fluid, separately⁽¹⁰⁾. The bulk modulus, defined as the ratio of the increment of pressure to the relative change in volume (dilatation) of a closed deformable region, was also measured in pathological cases such as in cases of hydrocephalus^(11,12,13).

Even with the compressibility assumption, the values of the bulk moduli indicate that the changes in volume cannot all be "absorbed" by the compressibility of the fluid, and a deformation of the outer shell of skull bones has also to be taken into account although that deformation may be small in magnitude. Thus the boundary conditions of the shell should no longer be assumed as zero lateral displacements. Instead, some displacements should occur and calculations predict that they are in the order of a few microns. This is in agreement with dial gauge measurements which, with the tips of the gauges tightly compressed against the parietal bones, yield values of 10-25 microns side displacement of these bones⁽¹⁴⁾.

There remains still a considerable gap between values of the free motion of the cranium that physicians feel during a cranial examination for mobility and those of the *constrained* motion measured by a mechanical dial gauge. The ratio of the two sets of values is about a hundred to one and this is explainable by virtue of the special morphology of the cranial bones.

The geometrical arrangement of the large bones of the cranium classify it as an "open structure". Such structures, composed of a finite

number of elements or of an infinite number of infinitesimal elements joined together, are characterized by having all elements contributing their small incremental motions along a common direction thus resulting, altogether, in a finite value of the integrated motion. The simplest example of an open structure is the coiled spring. Here, each infinitesimal element of the coil undergoes torsion which contributes a displacement component to the axial elongation of the spring. Each elongation is infinitesimal by itself. However, an infinite number of them are summed up along the same direction yielding, altogether, a finite value for the total elongation of the spring.

The skull bones are joined by soft-tissue sutures and the architecture of the complex is such that a small angular motion of each of the bones, which are subjected to internal pressure changes, yields a side displacement component the integral of which is noticeable and measureable. This is what the physician feels as a motion of the cranium and its rhythmicity - the cranial rhythm.

Sutherland⁽¹⁵⁾ regarded the cranial rhythm as a pivot of Cranial Osteopathy. He called the cranial articular structure "a primary respiratory system" which functions "in conjunction with the brain, the ventricles, and the intracranial membranes" and considered the physiological rhythms of the respiratory and cardiovascular systems as only "secondary" to the cranial rhythm. It was further postulated that in a normal living human all skull suture articulations remained mobile throughout life. Any abnormal impairment or restricting force upon this system by any of its related structures could cause symptoms which were often considered idiopathic or the result of neurotic malady. The primary objective of the physician was to trace the impairment and try to release it thus allowing the natural physiology to be restored to its natural state of equilibrium.

The normal range of frequency of the cranial rhythm is 10-14 cycles per minute (cpm). This rate is slower than the respiratory rate in the relaxed state by almost a third. The normal amplitude, identified with the lateral displacement of the parietal bone, may reach 1-1 1/2 mm. Changes of frequency, mostly a reduction up to 40%, have been correlated with psychiatric syndromes⁽¹⁶⁾ and when the therapy restored the rhythm to its normal level the syndromes subsided and vanished⁽¹⁶⁾. Mechanical measurements of the cranial rhythm have also been carried out and found to be in good agreement with the physicians findings^(17,14). Of the various techniques, strain plethysmography by means of high-extension, electrical resistance strain-gauges proved more sensitive and effective and this is described elsewhere⁽²⁾.

The Loewenstein Hospital in Ra'anana, which is the country's principal center for rehabilitation, accommodates in its intensive care units the most severe cases of brain damages, some of which are in coma for several years. A cranial examination of the patients there offers a wide coverage of cases from which comparative data can be accumulated. For that purpose, Dr. Upledger, during his recent visit, performed a cranial examination on eight patients who represented a cross section of the patient population in that hospital. The results of the examination are brought below. They are accompanied by a brief account of the patient's diagnoses and a description of their present state.

Results of Cranial Rhythm Examination

I. Patient H.Sh., Male, age 22. Admitted - 30.11.75. Still in hospital.

Diagnosis: venomous sting of scorpion on 14.10.1975. Patient in a chronic vegetative state.

- II. Patient M.Y., male, age 18. Admitted - 13.11.1977. Still in hospital. Diagnosis: as a result of road accident - severe brain stem lesion. Later course: respiratory arrest; removal of left epidural hematoma and hygroma; tracheostomy. Patient in chronic vegetative state.
- III. Patient H.S., male, age 17. Admitted - 28.1.1979. Diagnosis: spastic tetraparesis, failure of odontoid, respiratory failure. Bowels and bladder incontinence, contracture of lower limbs, connected to a Bennett respiration machine. Still in hospital.
- IV. Patient A.E., male, age 11. Admitted - 26.6.1979. Diagnosis: epilepsy, coma, transient tetraparesis, s/p suspect viral encephalitis. Had periods of ups and downs. Released August '79.
- V. Patient R.J., male age 27. Admitted - 10.6.1979. A UNIFIL soldier. As a result of a gun shot wound: diffuse peritonitis; laparotomy, partial resection of liver, nephrectomy. Fracture of right femur, left olecranon and humerus. After a cardiopulmonary resuscitation - patient in anoxic coma, tetraplegia, chronic vegetative state. Released - 5.10.1979 to be flown home to the Fiji Island.
- VI. Patient G.S., male, age 35. Admitted - 18.7.1979. Diagnosis: weakness in the upper and lower extremities; polineuropathia, walking difficulties, "gloves and boots" sensory disturbances. Still in hospital. Improvement noticed.
- VII. Patient S.H., male, age 17. Admitted - 20.10.1975. Injured in a road accident. Fracture in D8, D10 and in the skull base. Diagnosis: sensory disturbances from D8 downward, bowels and bladder incontinence. Blindness of the right eye. Released - 24.6.1977. Returned for two-week periods of hospitalization in May '78 and August '79. Services himself and independent on a wheel chair.

- VIII. Patient M.O., female, age 22. Admitted - 12.10.1975. Fell from a balcony and fractured D8. Diagnosis: complete paraplegia with sensory disturbances from D-6,7 downwards, bowels and bladder incontinence. Independent on a wheel chair. Hospitalized for pregnancy retention (miscarriage prevention). Released - 27.6.1976.
- IX. Patient I.M., female, age 24. Admitted - 1976, following an anesthesia for an oral surgery. Diagnosis - post cardiac arrest: brain damage due to anoxia, coma, tracheostomy, contracture of limbs. Patient I.M. passed away on 7.12.1979.

The above patients, except for patient I.M. (IX), were cranially examined by Dr. Upledger, in August, 1979, some of them in their beds and some while sitting in their wheel chairs. The examination consisted of the count of the cranial rhythm in cpm and the estimate of the percentage ratio of the pulsatory amplitudes of the cranial rhythm to the normal values. These ratios were measured - when possible - at three places: the head, the upper extremities and lower extremities. The following Table shows the results obtained:

Table - Count and amplitude ratio of cranial rhythm of patients with brain damages.

Patient	Sex	Age	Diagnosis	Cranial Rhythm (cpm)			Amplitude Ratio (%)		
				Head	Upper extremities	Lower extremities	Head	Upper extremities	Lower extremities
I. H.Sh.	M	22	Venomous sting of scorpion. Chronic vegetative state.	3	-	-	50	-	-
II. M.Y.	M	18	Severe brain stem lesion. Chronic vegetative state.	4	-	-	60	-	-
III. H.S.	M	17	Spastic tetraparesis	2.5	2.5	NR (*)	40	10	NR
IV. A.E.	M	11	Epilepsy. Transient tetraparesis.	2.5	6	6	30	30	30
V. R.J.	M	27	Anoxic coma. Chronic vegetative state.	4	NR	NR	50	NR	NR
VI. G.S.	M	35	Polyneuropathy (Guillain-Barre).	6	6	25	70	50	30
VII. S.H.	M	17	Paraplegia	5	5	18	50	50	50
VIII. M.O.	F	22	Paraplegia	7	-	16 (Rt) 4.5(Lt)	100	-	60 (Rt) 10 (Lt)
IX. I.M.	F	24	Anoxic coma. Chronic vegetative state.	-	-	-	-	-	-

(*) NR - No Rhythm detected.

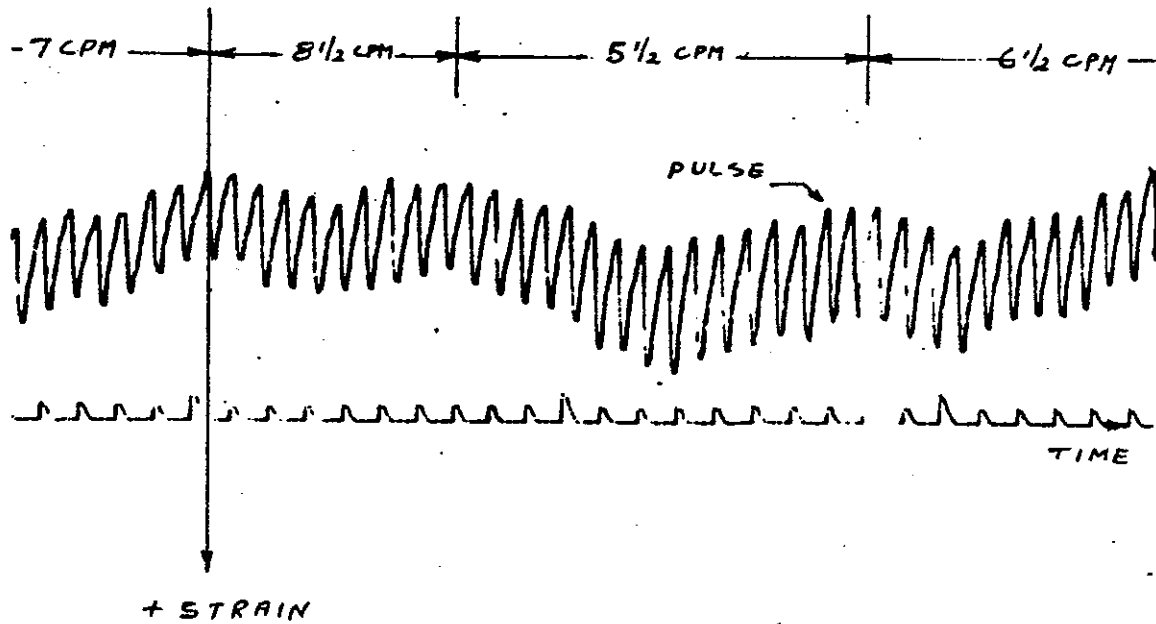
Measurements were later performed on patient G.S. (VI) and patient I.M. (IX). The technique - a strain plethysmography - by means of high-extension, electrical resistance strain gauges is described elsewhere⁽²⁾. The strain gauges were applied at the upper and lower extremities and picked up the pulses, of course, superimposed on the much slower dilations of the cranial rhythm. With respect to the latter, the frequency could immediately be determined. As to the amplitude ratio, it could be assessed from the ratio of the average pulse amplitude to that of the rhythm and compared with the normal values. Assuming the pulse amplitude to be practically constant with respect to the same patient, over a short period, the amount of the amplitude ratio of the cranial rhythm in reference to the normal pattern could also be assessed at least to a first approximation.

Figure 1a shows a section of the strain record measured continuously over the thumb of patient G.S. (VI).

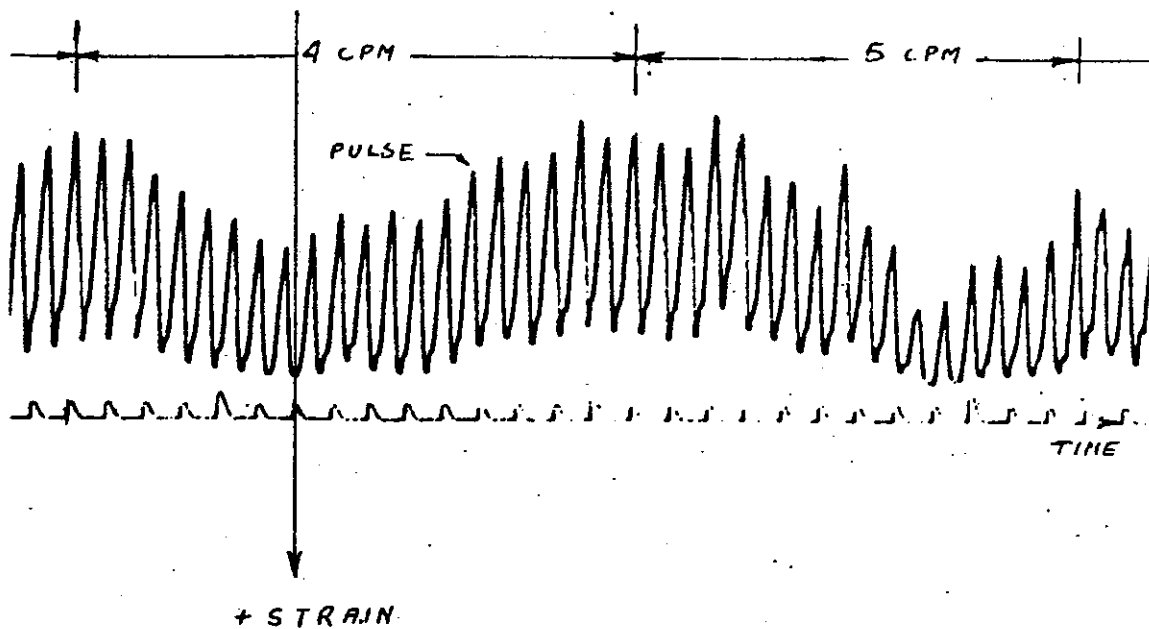
A time indicator marked each second by a small spike of the needle and every ten seconds by a large spike. When the gain sensitivity was doubled (Fig. 1b), so did the amplitude of the cranial rhythm. The frequency count for that patient was 5-6 cycles per minute and the amplitude ratio estimated, in comparison with a normal pattern as 40-50%.

When the gauge was applied over the right foot ankle the frequency pattern changed considerably to 22-25 cycles per minute. The pulse amplitude was much weaker and a fair assessment of the amplitude ratio could not be made. When the gauge was moved to the right foot thumb, the pulse record was even weaker but the frequency remained in the 20-25 cpm range. If these recordings are all compared with the corresponding results in the Table, the conformity is indeed striking.

Figure 2 shows a section of the strain tracing pertaining to the right hand thumb of patient I M (IX)



(a)



(b)

Fig. 1 Strain-time plethysmography record over patient G.S.'s thumb, with, (a) standard gain sensitivity, (b) double gain sensitivity.

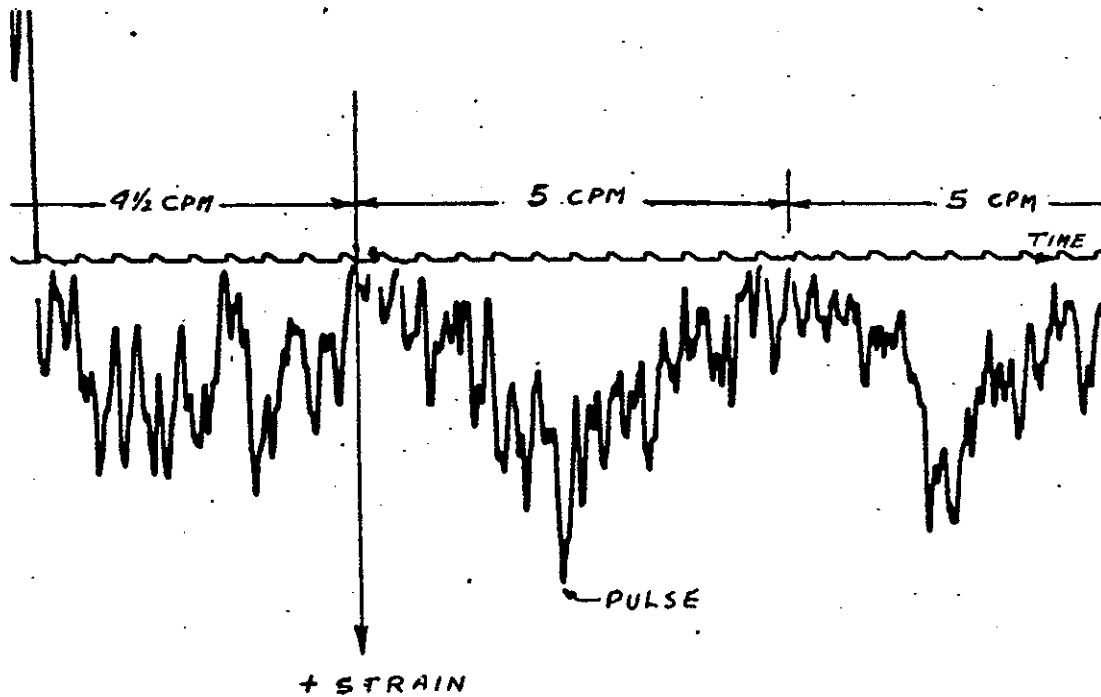


Fig. 2 Strain-time plethysmography record over the right hand of patient I.M.

Again, the frequency of the cranial wave was around 5 cpm and the amplitude ratio assessed as 30-40%. The strain record also picked up bursts of slow spastic dilatations of the upper extremity. The patient at that time, after 3½ years in a vegetative state, was in a desperate state. She passed away a few days later.

Observations

No conclusive results may as yet be deduced from the cranial examination of some of the patients at the Loewenstein Hospital suffering from long-standing spinal and brain damages. Nor are the measurements sufficient to corroborate to the theories underlying cranial mobility and rhythm. However, some observations can be made which are in support with the fundamental idea of cranial osteopathy and indicate how to proceed in that course.

1. A common feature of all the findings is a slow-down of the cranial rhythm to about one half of the normal level - in frequency and amplitude - when measured at the head. This level of activity is lower than the one measured in cases of psychiatric disorders⁽¹⁶⁾ where the rhythm was still in the range of 60-70% of the normal values.
2. The cranial rhythm is measureable all over the body and retains a constant value throughout. This conforms with a picture of a "primary respiratory system" which sustains itself to the very end of physiological life.
3. Exclusions of the constancy of the cranial rhythm were detected in some paraplegic cases. These were also the only cases where, at the lower extremities, values which exceeded the normal level of rhythmicity by almost a 100%, were measured. It should also be pointed out that these patients were later released from the hospital with a fair ability to function and to move around.
4. Although cranial rhythmicity has a neurogenic component to its effect primarily as an amplification circuit, at both ends of input and output it is a mechanical phenomenon. As such it is also amenable to sensitive and non-invasive mechanical measurements. They, undoubtedly, will throw more light on the subject when more data is accumulated.

Acknowledgement

This research has been sponsored in part by the Julius Silver Institute of Biomedical Engineering Sciences and Grant 130-077.

References

1. Karni, Z. and Upledger, J.E.: Early steps of cranial therapy in Israel. Julius Silver Institute of Biomedical Engineering Sciences, Technion - Israel Institute of Technology, Haifa, Israel. Research Report 79-1979.
2. Upledger, J.E. and Karni, Z.: Strain plethysmography and the cranial rhythm. Proc. XII Inter. Conf. on Med. and Biol. Eng. Jerusalem, Israel, August 19-24, 1979, Part IV, 69.5.
3. Livingston, R.B., Woodbury, D.M. and Patterson, J.L. Jr.: Fluid compartment of the brain; cerebral circulation. In: Ruch, T.C. and Patton, H.D. (eds.): Physiology and Biophysics, 19th ed. W.B. Saunders, Philadelphia, 1965, 935-958.
4. Agarwal, G.C.: Fluid flow - a special case. In: Brown, J.H.V., Jacobs, J.E. and Stark, L. (eds.): Biomedical Engineering. F.A. Davis Co., Philadelphia, 1971, 69-81.
5. Marmarou, A., Shulman, K. and LaMorgese, J.: Compartmental analysis of compliance and outflow resistance of the cerebrospinal fluid system. J. Neurosurg. 43, 1975, 523-534.
6. Lewer Allen K. and Bunt, E.A.: Dysfunctioning of the fluid mechanical craniospinal systems as revealed by stress/strain diagrams. Proc. Int. Conf. on Bioengineering, Cape Town, South Africa, April 1977, 132-151.
7. Monro, : Observations on the structure and functions of the nervous system. Edinburgh, 1783.
8. Kellie, : Trans. Med. Chir. Soc. Edinburgh, 1824.
9. Weed. L.H.: The cerebrospinal fluid. Phys. Rev. 2, 1922, 171-203.
10. Lewer Allen, K. and Sun, H.A.: A study of the pressure of the cerebrospinal fluid in man by remote monitoring through the skull. CSIR Symposium on Biotelemetry, Pretoria, 1971.
11. Bunt, E.A., Pastall, G., Smoleniec, J. and Lewer Allen, K.: A measurement of the effect of an enclosed volume of air on the compressibility of a stimulated cranial cavity. Med. & Biol. Eng. 14, 1976, 318-320.
12. Haar, F.L. and Miller, C.A.: Hydrocephalus resulting from superior vena cava thrombosis in an infant. J. Neurosurgery 42, 1975, 597.
13. Langfitt, T.W.: Increased intracranial pressure. Clinical Neurosurgery, Chap. XXI, Congress of Neurological Surgeons, Vol.16 Williams and Wilkens, Baltimore, 1968.

14. Frymann, V.M.: A study of the rhythmic motions of the living cranium.
Jour. Amer. Osteo. Assoc. 70, 1971, 928-945.
15. Sutherland, W.G.: The Cranial Bowl. Free Press Co., Monkato, Minn.,
1939, 140 pp.
16. Woods, J.M. and R.H.: A physical finding related to psychiatric disorders.
Jour. Amer. Osteo. Assoc. 60, 1961, 988-993.
17. Moskalenko, V.Y. and Naumenko, Y.: Cerebral pulsation in the closed
cranial cavity. Izv. Akad. Nauk SSSR (Biol.) 4, 1961, 620-629.

