

CASE STUDY 1.0

ABDOMINAL
LYMPHODYNAMIC EDEMA

BY

David Doublestein, MSPT

DM is a 65 year old female referred to the clinic on 04/13/09 for lymphedema of the abdomen. DM is unemployed and she lives independently. DM current medication list includes Plavix, Crestor, Synthroid, Lasix, Vicodine, and Fetenol patch. Patient presents to the clinic reporting that she has had significant complications with obesity since 1996. DM started developing some edema in 2001 within the abdominal region secondary to a flesh eating bacteria that she contracted in April of 2001. This flesh eating bacteria occurred in the viscera and she had surgical intervention to remove the flesh that was infected by this bacteria. The edema on the left side of her abdomen ever since 2001 has been progressively getting worse. DM has had a pendulus abdomen for a number of years, but the edema has progressively been worsening on the left side. The pendulus mass of edema affects her with low back pain and makes walking difficult. DM also has complications of constipation. She has not had any recent surgical interventions to the viscera or any lymph nodes removed. Her medical history does not lead to concerns of primary lymphedema. Patient is unable to lay on the right side. She sleeps in a hospital bed, and is able to lay supine. Patient also notes some left thigh edema. She did have an episode of cellulitis in January, 2009. The cellulitis was in the left lower leg. Patient is not a surgical candidate for debulking procedures due to her history of a bacterial infection.

Observations: Patient is morbidly obese with presentation of edema in the abdomen. There is also notable edema in the medial aspect of the left knee and thigh.

Range of Motion: Bilateral upper extremity and lower extremity AROM is within functional limits without increased pain levels.

Strength: Bilateral upper extremity and lower extremity gross manual muscle testing is a 4/5 without increased pain levels.

Clinical Tests: Circumferential measurement of the edematous lobule is 89 cm. Photographs were taken of the edematous pendulus abdomen (**figure 1.0**).

Manual Tests: There is a presentation of a stage 3 lymphedema of the abdomen on the left side. There is presentation of papillomas covering the pendulus abdomen. Firm fibrotic tissue is noted. Absence of pitting edema is noted.

Pain Levels: Patient does report some pain with sitting and walking that is a 5 to 6/10 on a 0-10 scale.

Treatment Procedures: Six treatment sessions beginning of 4/20/08 were conducted which included lymph drainage therapy, manual lymphatic mapping, fibrotic tissue techniques, and kinesiotaping of the pendulus abdomen. Each session lasted 1 hour in duration. Two sessions included ½ hour of aquatic exercises.

Outcomes: DM suddenly became ill on 05/03/09 and was hospitalized. DM did not return to therapy for additional treatment secondary to her illness. At the time of her last two treatment sessions the fibrosis had decreased significantly. Circumferential measurement were not ascertained secondary to DM not returning to the clinic. The treatment measures seemed to be appropriate and progressing DM to improved outcomes. The aquatics seemed to offer this patient freedom to exercise and ambulate without difficulties. This exercise would have been beneficial in weight loss and the water compression and buoyancy of the fatty tissue may have improved the outcomes. The maintenance of this condition was not fully addressed. I believe that ultimately patient massages, kinesiotaping, and aquatics may have been the best maintenance options. An abdominal support may also be beneficial (**figure 2.0**).

FIGURE 1.0 PHOTOGRAPHS TAKEN 4/13/09

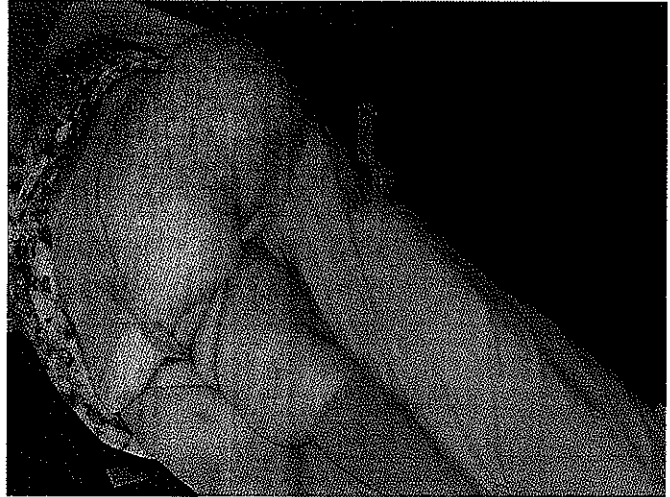
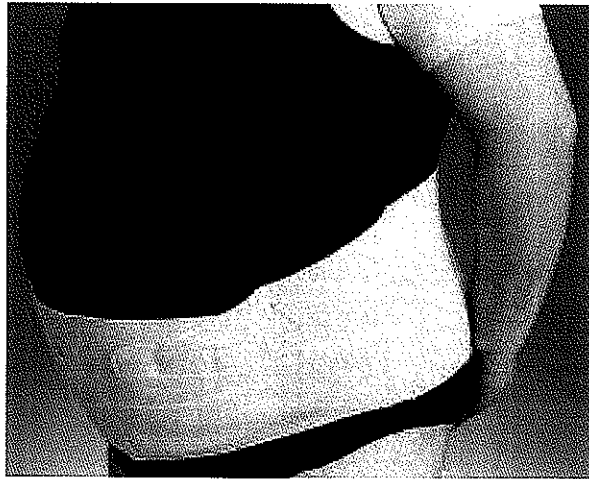


FIGURE 2.0



I DECLARE THAT THE INFORMATION PROVIDED IN THIS CASE STUDY ARE TRUE AND ACCURATE TO THE BEST OF MY ABILITY. PUBLICATION OF THIS CASE STUDY IS PERMISSABLE BY MYSELF AND THE CLIENT.

 5/11/09

David Doublestein, MSPT, LLCC