

Case History
Beverly Waldeisen, OTR/L, CLT-LANA

J.K. is an 82 year old male, retired automobile dealership owner, with a diagnosis of bilateral lower extremity chronic venous insufficiency. He suffered a deep vein thrombosis in the right groin nearly 15 years ago. He reports the swelling never resolved even though he had consistently worn a class II (30-40 mm Hg) thigh high graded compression stocking. No other treatment was ever given for this condition. His medical history is significant for hypertension; emphysema; and a GI bleed the previous year.

Initial Measurements:

	Right	Left
Foot	26.5 cm	26.5 cm
Ankle	28.0 cm	27.5 cm
10 cm proximal	26.3 cm	30.8 cm
20 cm prox.	33.2 cm	41.2 cm
30 cm prox.	38.0 cm	39.2 cm
40 cm prox.	42.8 cm	46.0 cm
50 cm prox.	45.1 cm	46.2 cm
60 cm prox.	61.5 cm	61.5 cm
70 cm prox.	59.3 cm	57.5 cm

Patient complained of long standing swelling that worsened throughout the day and did respond somewhat to elevation. He did not complain of pain in the edematous tissues, but only in the right knee that was in need of surgical repair. He presented with appearance of lipodermatosclerosis of right lower leg with thickened red/brown stained skin around ankle and the inverted champagne bottle shape. He had a small weeping lesion on posterior lower leg. He reported past episodes of weeping from this leg. Left leg also showed a small amount of hemosiderin staining of the skin and had a small amount of fluid to palpation. Varicosities were noted in posterior left calf, and spider veins were present bilaterally in medial malleoli areas. Patient was treated with the standard lymph drainage protocol of manual techniques, therapeutic exercise, and compression wrapping. He was seen daily for an average of 45 minutes per session for a total of 14 sessions, 10 devoted to volume reduction and 4 focused on garment management, over a period of 3 weeks. He progressed well with the small weeping lesion closing within the first few days of treatment. By the end of treatment he had reduced volume of 22.0 % in the right leg and 5.2 % in the left leg. He was fitted with Circaid Ready Fit 2000 leggings with ankle foot wraps. He was very compliant with all parts of the protocol throughout the duration of

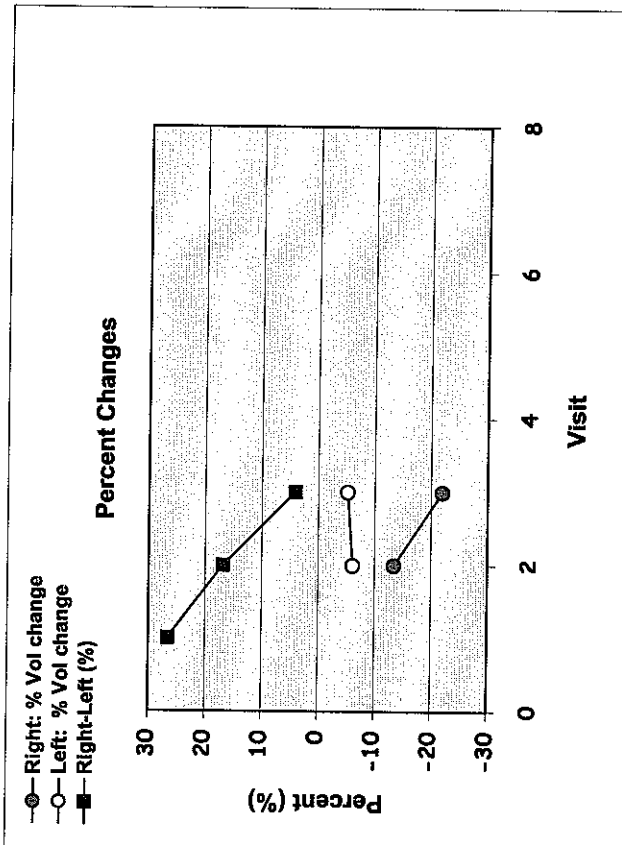
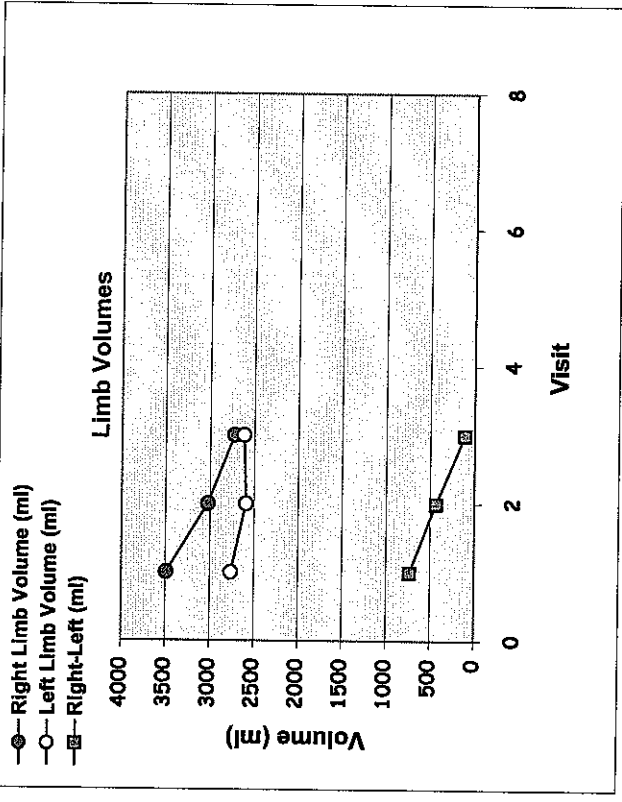
treatment. He was independent in application of the leggings by end of treatment and was very pleased with the outcome.

Several months after end of treatment he underwent a right total knee replacement. Initially he suffered a significant increase in the total leg edema that was again controlled with a short duration of the same treatment, by a different therapist, until he was able to again don the compression legging. At last contact he was continuing with independence in his home program and garment management.

The above information is true and accurate to best of my knowledge.

Beverly Waldeisen, OTR/L, CLT-LANA
Beverly Waldeisen, OTR/L, CLT-LANA

Visit	1	2	3	4	5	6	7	8	9	10	11	12	13	14	15	16	17	18	19	20	21	22	23	24
Right Limb Volume (ml)	3490	3022	2722	0	0	0	0	0	0	0	0	0	0	0	0	0	0	0	0	0	0	0	0	0
Left Limb Volume (ml)	2758	2588	2614	0	0	0	0	0	0	0	0	0	0	0	0	0	0	0	0	0	0	0	0	0
Right-Left (ml)	732	434	108																					
Right-Left (%)	27	17	4																					
Right: % Vol change																								
Left: % Vol change																								

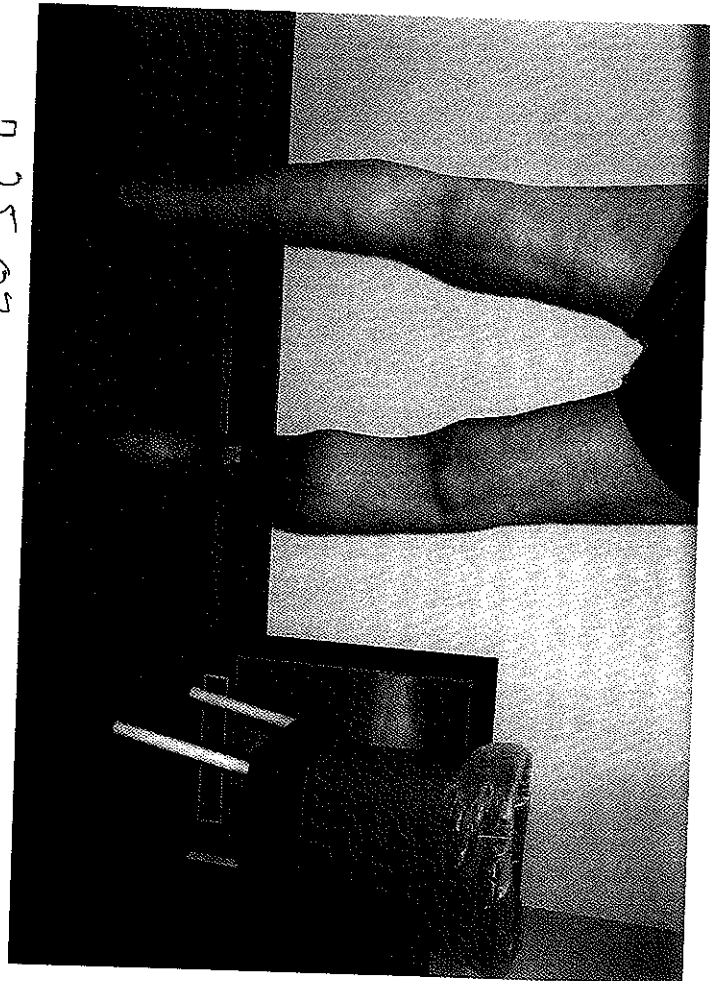
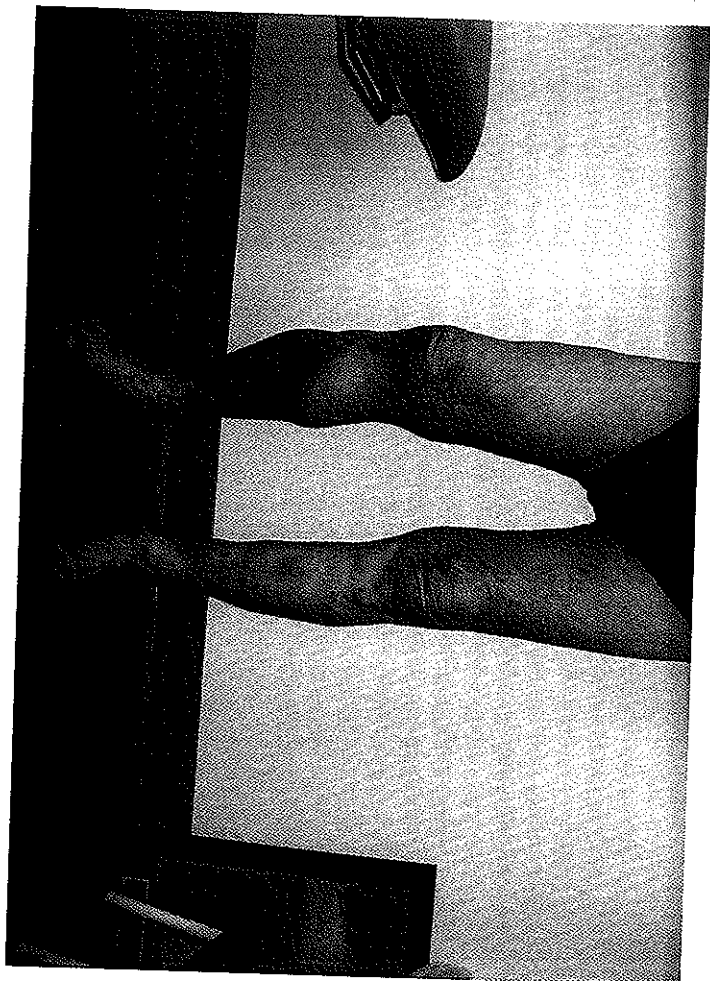


Note: In the above graphics, Visit refers to patient visits during which limb volume measurements were made and recorded
The AFFECTED Limb(s) of this patient is **BILATERAL**

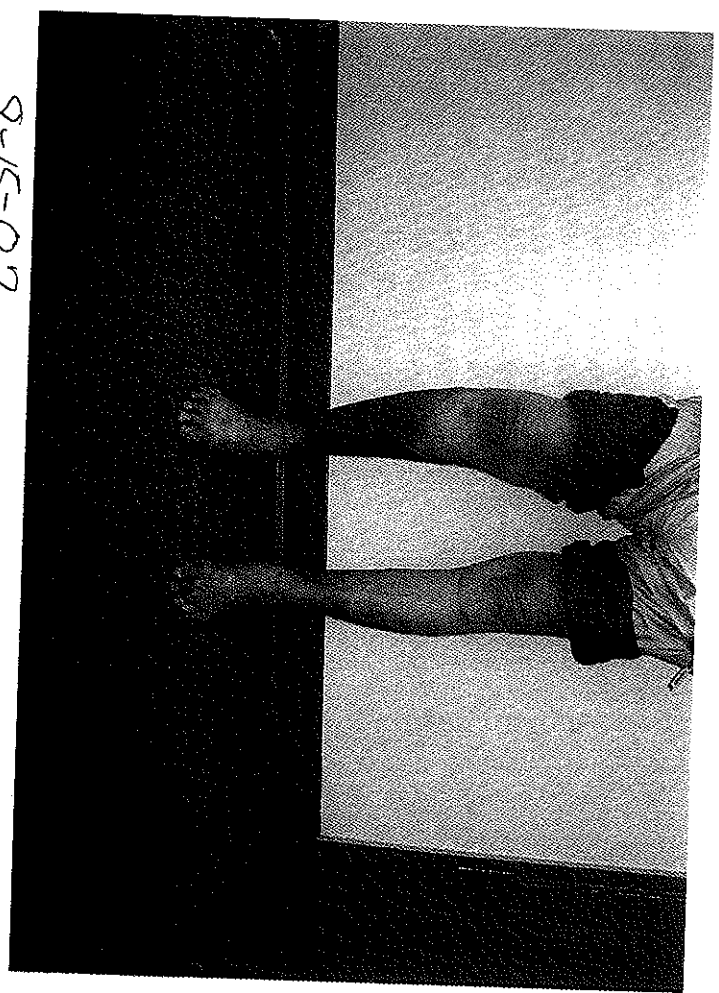
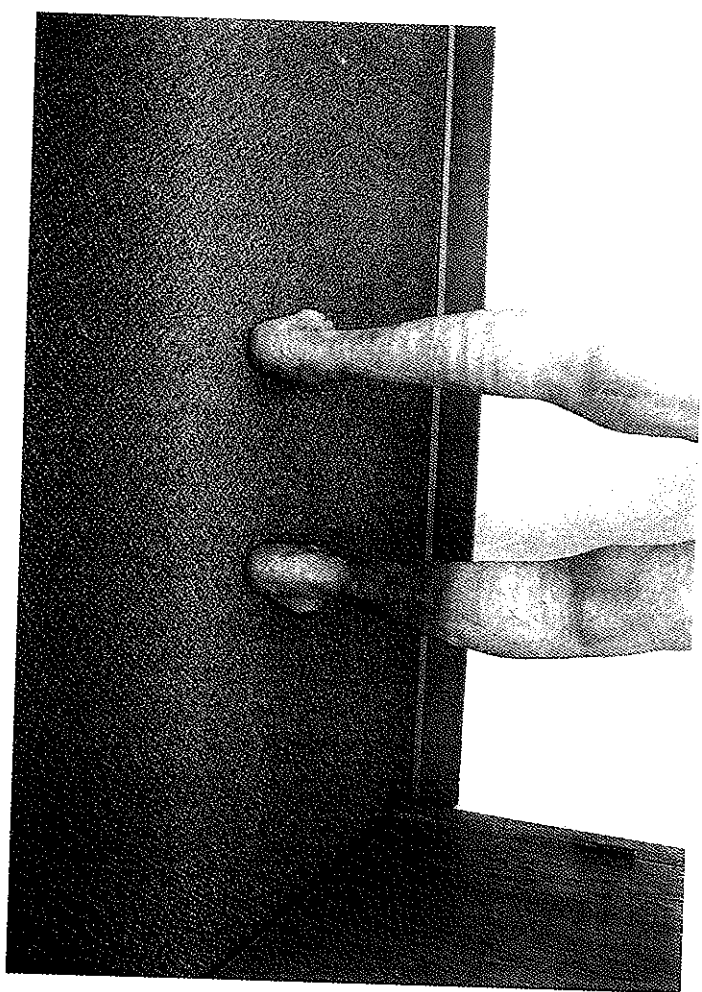
Comments

View

B.K.



7-25-07



8-15-07