

LYMPHEMA CASE STUDY#1

Patient is a 47-year-old female originally seen for evaluation in the PT clinic on 5/6/08 with diagnosis of severe bilateral lower extremity lymphedema grade 3, left greater than the right with open wound.

Patient was an independent vice president of a local computer company which required her to do a fair amount of traveling. Approximately in June '07 she began noticing swelling in her left lower extremity. She immediately followed up with physician regarding this and was told that she was obese and needed to go on a diet. Following this, she began diet in which she lost 75 pounds, but there was no change in her legs, and in fact, they had worsened. In January '08 she needed to quit her job, due to the swelling and in her inability to ambulate. She was confined to her house and noted that the swelling was becoming greater, although there were changes in the size of her arms, as well as her neck and face. On February 10, 2008, while vacuuming her apartment and bending over, the back of her leg "exploded" with patient having severe bleeding. She was admitted to the Emergency Room and underwent debridement. Wound size at that time was measured at 6 inches in diameter x 6 inches deep at its worst. Admitting physician had reported that there was an infection that had set in deep in her leg with resultant necrosis of tissue and one of the major veins in the posterior aspect of her leg. Following this, she was sent home in early March and was seen by Home Health for wound management. She was referred in April to a plastic surgeon regarding as kin graft or liposuction to close the wound and decreased edema in the lower extremities. At that time, the plastic surgeon declined, stating there was too high of a risk.

Patient was seen for evaluation in physical therapy after a diagnosis of lymphedema had been made of the lower extremities. In the mean time, she had begun developing edema in the right lower extremity as well. On initial evaluation, she presented with severe grade 3 lymphedema of the left lower extremity. Wound measurements were the same 6 inches x 6 inches in diameter x 6 inches deep with tunneling noted deep into the posterior aspect of the thigh. She required frequent break every 10 feet in order to rest, secondary to the extreme weight of her legs. They were in a state of severe lymphedema with patient exhibiting two large lobules over the medial aspect of the left leg, hardening and thickening of the tissue superficially with fibrosis noted around the wound bed and medial thigh and to a lesser degree, she had edema extending distally below the knee, but this was much less. In the right lower extremity, she exhibited grade 2 lymphedema of the proximal thigh. Patient also was affected in the groin region.

Secondary to extreme difficulty with getting out of her house into a car into the clinic, it was decided that home care would be best for patient. On her initial visit she was taught diaphragmatic breathing, lymphatic drainage techniques, emphasizing proximal movement of fluid from the lower extremities into the abdomen after opening clavicular and axillary regions on both sides. She was encouraged to have her feet elevated frequently through the day with gravity assist. Bandaging was not performed on patient's first visit. Patient's second visit was performed in the home, secondary to patient's extreme difficulty with maneuvering. At this visit, both myself and Home Care therapist met with patient and initiated bandaging for the left lower extremity. Secondary to patient's lack of funds, high numbers of bandages needed, she was limited as to changes of bandages required. She was shown, along with Home Care therapist, proper bandaging techniques from the toes up to the hip. This was initiated for the left leg only. On patient's third visit, it was discovered that she was unable to maneuver with the use of bandages. Her knee could not bend, secondary to high volume of fluid and it was decided that the knee would be kept open with only the lower and upper leg bandaged to provide for flexible knee.

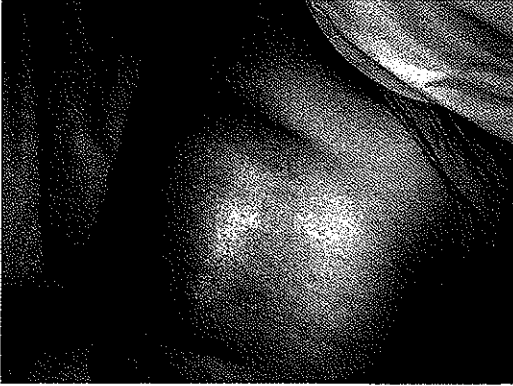In the meantime, patient was shown full lymphatic drainage for the entire body to be performed daily. She was encouraged to drink water frequently. It was immediately noted post bandaging that the volume and frequency of urination increased.

Zm

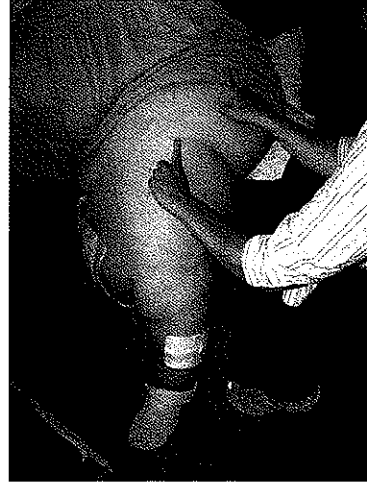Mike Voelkel PT.
Mike Voelkel, PT, #15687

addendum: this patient is continuing to undergo treatment for her wound at Johns Hopkins and will be set up on a wound vacuum. she will eventually be returning to the clinic and we will work on continuing to reduce her. Mike Voelkel 9/13/08

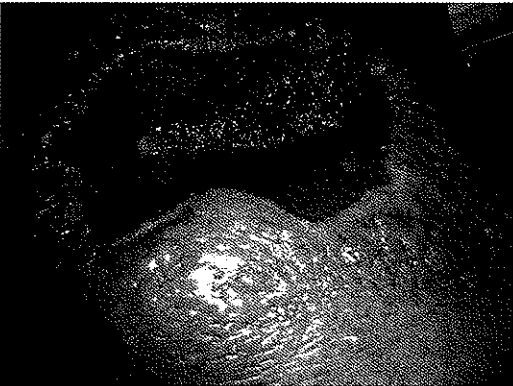
06/11/2008



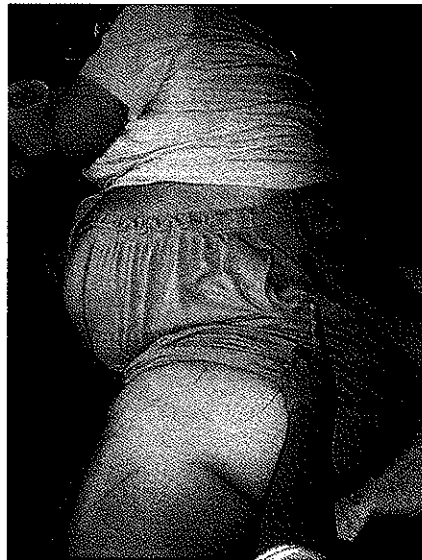06/11/2008



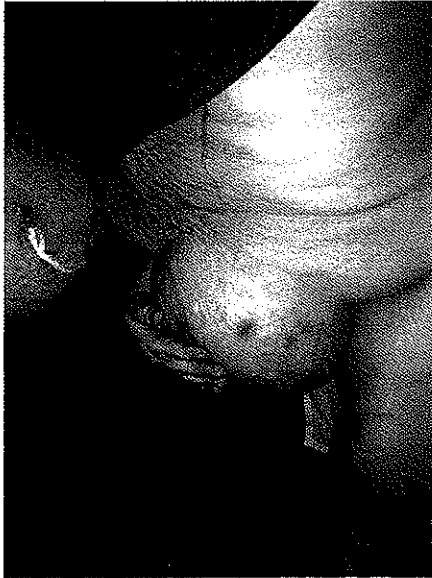06/11/2008




6/11/2008



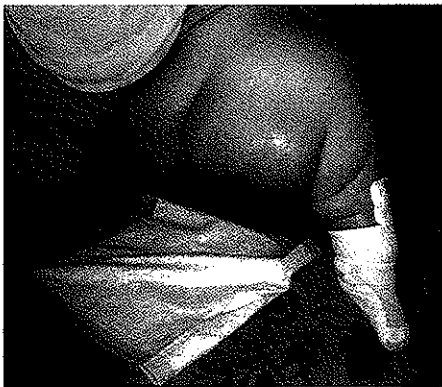05/14/2008



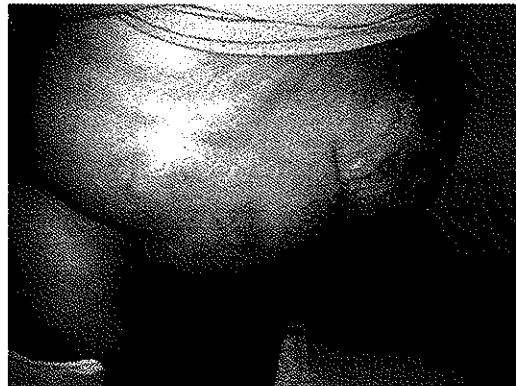05/14/2008



06/11/2008



6/11/2008



6/11/2008

