



Prevention and Rehabilitation

The effect of visceral manipulation on Diastasis Recti Abdominis (DRA): A case series

Brandi Kirk^a, Teresa Elliott-Burke^{b,*}^a Kirk Center for Healthy Living, Faculty The Barral Institute 16618 W 159th Street, Suite 402, Lockport, IL, 60441, USA^b Physical Therapy Institute, Midwestern University Multispecialty Clinic, 3450 Lacey Road, Downers Grove, IL, 60515, USA

ARTICLE INFO

Article history:

Received 7 April 2019

Received in revised form

18 March 2020

Accepted 7 June 2020

Keywords:

Visceral manipulation (VM)

Inter-rectus distance (IRD)

Jejunioileum

Parietal peritoneum

ABSTRACT

Background: Diastasis recti abdominis (DRA) is a condition that affects many postpartum and older women, often due to pregnancy-related issues and heavy lifting. Published research on nonsurgical DRA treatment has primarily focused on exercise to correct or prevent this dysfunction. A survey of women's health physical therapists identified that visceral manipulation and other interventions are utilized to treat DRA. No literature exists to identify the specifics of visceral manipulation or its effect on DRA.

Study design: This case series is a retrospective chart review of three female patients with DRA who received visceral manipulation.

Case description: The ages of the patients were 33, 37, 39 years old and all were positive for DRA based on inter-rectus distance (IRD) described as greater than two finger-width measurements at one of three measurement sites. Patients presented with chief complaints of low back pain, abdominal pain, and vulvar burning and itching. All women were gravida two and para two. Each patient received at least four treatments of visceral manipulation (VM).

Outcomes: VM decreased the IRD, decreased numeric pain rating scores, and improved functional activities in three women with DRA. Improvements were also seen in bladder and bowel symptoms.

Discussion: Four treatments of visceral manipulation appear to be effective in decreasing DRA measurements in three women. DRA measurements improved to two finger-widths or less above, at, and below the umbilicus. The changes remained stable for six to sixteen months.

© 2020 The Author(s). Published by Elsevier Ltd. This is an open access article under the CC BY-NC-ND license (<http://creativecommons.org/licenses/by-nc-nd/4.0/>).

1. Introduction

Diastasis Recti Abdominis (DRA) is a separation of the rectus abdominis muscles at the linea alba (Irion and Irion, 2010). Risk factors for DRA include multiparity, multiple gestations, larger babies, greater weight gain, birth by cesarean section (Irion and Irion, 2010) and heavy lifting ≥ 20 times per week (Sperstad et al., 2016). The purported functional consequences of separation of the rectus muscles include altered trunk mechanics, lumbar pain, abdominal and pelvic region pain (Parker et al., 2008) and pelvic floor dysfunction (Spitznagle et al., 2007). Several treatment techniques, including walking, abdominal strengthening, specific transverse abdominis (TrA) strengthening, pelvic floor exercises, education, abdominal binder, soft tissue mobilization, trigger point release, myofascial release, abdominal taping (Benjamin et al., 2014; Keeler

et al., 2012), have been reported to address DRA.

DRA has been observed frequently in pregnant (Sperstad et al., 2016; Mota et al., 2015), postpartum (Sperstad et al., 2016; Mota et al., 2015), and postmenopausal women (Spitznagle et al., 2007). Studies of the prevalence of DRA in pregnant women have shown ranges from 33.1% at week 21 (Sperstad et al., 2016) to 100% at week 35 (Mota et al., 2015). Occurrence of DRA in 541 older women, mean age 54.81 ± 15.53 years, who presented to a urogynecological clinic was 52% (Spitznagle et al., 2007).

The rectus abdominis plays a role in trunk mobility and stability, posture, and respiration (Lee et al., 2008). Any defect, such as a separation in this structure, may impair functional stability. Limitations may include issues with respiration, spinal mobility, spinal stability, posture and defecation which requires increased intra-abdominal pressure. The findings, in the currently available research, are mixed as to the role of DRA in pelvic dysfunctions and lumbopelvic pain (Sperstad et al., 2016; Parker et al., 2008). Spitznagle et al. (2007) found that patients with DRA were 1.79 times more likely to present with one or more support-related

* Corresponding author.

E-mail address: tellio@midwestern.edu (T. Elliott-Burke).

pelvic floor disorders, such as stress urinary incontinence, fecal incontinence, and pelvic organ prolapse. It could not be determined if the DRA or pelvic floor disorder came first. Liaw et al. (2011) found that the size of DRA was negatively correlated with abdominal muscle function.

Therapeutic exercise is the most common, non-surgical, technique utilized by physical therapists to treat DRA (Keeler et al., 2012). The following studies have examined the effect of prenatal and postpartum exercise on DRA. Chiarello et al. (2005) found that the prevalence and magnitude of DRA was greater in non-exercising than in exercising pregnant women who performed abdominal muscle strengthening, pelvic floor exercises and received education in prenatal body mechanics. Zappile-Lucis (2009) reported a successful return to function and decreased pain of a postpartum woman with DRA after a six-week course of treatment consisting of core strengthening, stabilization, aerobic activity, neuromuscular re-education, training TrA and patient education to avoid strengthening of the rectus abdominis. Mahalaskshmi et al. (2016) showed postpartum DRA corrective exercises to be effective in reducing DRA. In a recent pilot study, a 12-week exercise program targeting the TrA showed a decrease in inter-rectus distance and was not more significant than TrA exercises and taping of the DRA (Tuttle et al., 2018). Also, a systematic review including eight studies and 336 women examined the effects of exercise on DRA concluded that exercise may or may not help to prevent or reduce DRA during the prenatal and postpartum period (Benjamin, et al 2014). Dufour et al. (2019) in reporting on the Delphi DRA Consensus Study generated 28 expert-based recommendations from 21 Canadian physical therapists regarding the conservative treatment of DRA including general, prenatal, intra-partum, and postpartum suggestions. These recommendations primarily focus on exercise, posture, functional activities, such as those that increase intra-abdominal pressure, and breathing (Dufour et al., 2019). All of these studies recommended further investigation of specific exercises and other therapy techniques to gain a better understanding of the evaluation and treatment of DRA.

In a survey of women's health physical therapists (PTs), therapeutic approaches utilized to treat DRA included therapeutic exercise, manual therapy, therapeutic modalities, abdominal binders, and home exercises (Keeler et al., 2012). The most commonly reported therapeutic exercise techniques were transverse abdominis muscle training (89.2%), pelvic floor muscle training (87%) and The Elizabeth Noble Technique of manual approximation of the rectus bellies with a partial sit-up (62.5%) (Keeler et al., 2012). In this survey, manual therapy included visceral manipulation (VM), myofascial release, muscle energy technique, and trigger point release. Of the 274 therapists who responded positively to the use of manual therapy, 21% reported utilizing VM (Keeler et al., 2012). No further description of the VM techniques was given in this study or in any other literature at this time.

The need to further investigate fascial/VM techniques is also confirmed by a plastic surgery study that concluded the bulge and stretching of the anterolateral abdominal wall are caused by the stretching of the entire musculofascial abdominal wall and not only the linea alba (Brauman, 2008). Additionally, Diane Lee (2017) in *A Clinical Guide for Those Who Are Split Down the Middle*, concludes that suboptimal strategies involved in DRA and other pregnancy-related conditions may be driven by impairments in multiple systems such as, articular, neural, myofascial and visceral. Furthermore, she states each individual with a DRA requires a program to address specific deficits within the abdominal neuromyofascial and visceral systems (Lee, 2017). Lee et al. (2008) also discussed the role of fascia in DRA. They concluded that pregnancy has an adverse impact on the fascial support system of the abdominal wall and that

fascia should be considered in the treatment of pelvic girdle pain, urinary incontinence and breathing disorders.

VM is gentle, specifically placed manual forces that encourage normal mobility, tone, and inherent motion of the viscera, connective tissue, and other structures where physiologic motion has been impaired (Barral et al., 2013). The purpose of VM is to recreate, harmonize, and increase proprioceptive communication in the body to enhance its mechanism for better health (Barral et al., 2013). VM is theorized to work through the proprioceptors and mechanoreceptors to assist the body in healing itself. There is limited published research on VM. One study found that VM of the sigmoid colon immediately decreased pain in the segmentally related muscular tissue (McSweeney et al., 2012). Several studies utilized VM combined with other treatments as an intervention to treat a variety of conditions. A case study utilized VM as one of several treatments to resolve constipation (Archambault-Ezenwa et al., 2016). In a case series of five children with cerebral palsy and chronic constipation, VM and neural manipulation increased the number of bowel movements per week (Zollars et al., 2019). Eleven concussed patients showed a significant improvement in pain intensity, ROM, memory, cognition and sleep when treated with VM, craniosacral therapy, and neural manipulation (Wetzler et al., 2017). VM has also been shown to have a role in the prevention and treatment of post-operative adhesions in rat models (Bove and Chapelle, 2012).

A decrease in DRA was noted by one of the authors, a Barral Institute instructor, when demonstrating VM of the jejunioileum to a class. The physical therapist instructor then did a chart review to find three charts utilizing VM in the treatment of DRA. The physical therapist utilizing these techniques has an extensive knowledge and application of VM and specializes in pelvic conditions, GI dysfunction, and chronic orthopedic issues. This case series describes the use of VM to treat DRA in three patients receiving physical therapy (PT).

2. Study design

A retrospective chart review was conducted to identify patients with DRA that received primarily VM in the first four sessions. The criteria for selecting patients were DRA, identified by one of the authors at initial evaluation, and primary treatment of VM for the first several physical therapy sessions. Chart reviews were conducted until three cases were found that met the criteria between December 2014 and December 2016. This case series received Institutional Review Board (IRB) approval from Midwestern University Office of Research and Sponsored Programs. All patients

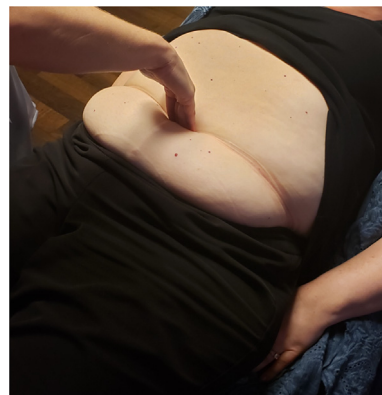

Fig. 1. Finger-width measurement of DRA at umbilicus.

provided written consent to utilize their chart data for this study.

3. Case descriptions

A total of three patient charts were reviewed. Patients were 33, 37, and 39 years old. Each patient presented with a parity of two. Patients were referred to an outpatient physical therapy practice for a variety of problems including low back pain, abdominal pain, and burning/itching of vulvar tissue. All three patients were evaluated and treated by the same two physical therapists. Upon initial evaluation, all patients were positive for DRA with measurements of greater than two finger-widths in at least one of the three measurement sites. The sites were three finger-widths above the umbilicus, at the umbilicus, and three finger-widths below the umbilicus (see Fig. 1 for finger-width DRA measurement technique). Initial evaluation findings and clinical reasoning lead one of the authors to address DRA as the first step in the patients' treatment protocol. DRA measurements were taken at the initial evaluation and the conclusion of each treatment session. After the first four visits, each patient received additional physical therapy. The remainder of the treatment sessions focused on addressing the additional objective findings.

3.1. Patient One

3.1.1. Evaluation

Patient was a 37-year-old female who presented to physical therapy with the chief complaint of low back pain that had been constant since her Cesarean Section (C-section), which was six years ago. The pain was worse in the morning and she had difficulty bending over. She also complained of right knee pain. Her treating diagnosis was low back pain and adherent scar. She had a Mirena IUD (inserted two years ago) in place at evaluation and she took Aleve as needed. Her past medical history (PMH) was one scheduled C-section due to her child being breech and one vaginal birth after C-section. Her functional impairment was difficulty taking care of her first-grade child and four-year-old at home due to her pain. She also had difficulty bending toward her right side which affected her everyday activities. Back pain was an intermittent achiness with stabbing. Pain assessed on visual analog scale (VAS) best pain: 0/10, present pain: 2/10, worst pain: 4/10. Physical findings included decreased segmental motion at L1-5 with lumbar flexion, lumbar active range of motion (AROM) as a percentage of normal ROM included: left side bending: 50% and right side bending: 5% and painful, flexion: 100% but compensating and all other motions were 50%. Gross strength was abdominals 3/5, back extension 4/5 and bilateral lower extremities 4/5. Accessory movement included decreased right side bending with activities of daily living (ADLs) and decreased lumbar rotation with ambulation. Her posture included pes cavus, right leg externally rotated, left shoulder depressed and left side bent posture. Palpation at evaluation revealed restrictions along her superior and inferior leaf of her mesenteric root of the jejunioileum, restrictions along her mesentery of the jejunioileum, restricted loops of her jejunioileum just superior to her suprapubic scar and restrictions along her uterus. Special Tests included a test for DRA using finger-width measurements with the patient in a supine position. The measurements were one and one-half finger-widths above umbilicus, three finger-widths at the umbilicus and two and one-half finger-widths below umbilicus. Assessment of the patient was significant DRA was potentially causing her back pain since she was unable to efficiently recruit her abdominal musculature to protect and support her back. The DRA may also have prevented her from supporting her abdominal organs and thus this may have created a tension along her back. Previous treatments for this condition were

abdominal strengthening exercises at the gym on her own, but she stated that nothing has been able to help her back pain.

3.1.2. Intervention

Visit One (Evaluation): VM consisting of mobility of the jejunioileum root, jejunioileum mesentery, loops of jejunioileum, and motility of the jejunioileum.

Visit Two: VM consisting of mobility of the jejunioileum root, jejunioileum mesentery, loops of jejunioileum, right uterosacral ligament and motility of the jejunioileum and uterus.

Visit Three: VM consisting of mobility of the right phrenicocolic ligament, hepatocolic ligament, cystocolic ligament, Fascia of Toldt with ascending colon and motility of the large intestine.

Visit Four: (IUD removed by MD before this visit.) VM consisting of mobility of the right uterosacral ligament, left broad ligament, motility of the uterus, and manual articular techniques to the right and left knees.

Visit Five: VM consisting of mobility of the left uterosacral ligament, motility of the uterus; manual articular techniques to S3-4 longitudinal compression, sacral pumping, and right knee and exercises for pelvic floor relaxation and diaphragmatic breathing.

Visit Six: VM consisting of mobility of the rectum, Ligament of Cleyet, inferior parietocecal ligament, motility of the rectum and cecum and exercises for diaphragmatic breathing.

Visit Seven (Discharge): Manual articular techniques to the left hip, right knee, and right ankle and exercises for diaphragmatic breathing.

3.1.3. Discharge

Patient received seven sessions of physical therapy at a frequency of once every three to four weeks over 18 weeks. Therapy consisted of VM including motility and mobility techniques, manual articular techniques, pelvic floor relaxation, and diaphragmatic breathing. No home exercise program (HEP) was issued to the patient. The first three sessions were strictly VM. DRA improved from one and one-half finger-widths to zero finger-widths above umbilicus, three finger-widths to one finger-width at umbilicus and two and one-half finger-widths to zero finger-widths below umbilicus. This change occurred in the first three sessions and was then maintained for the rest of the sessions that were spaced over three more months. Lumbar AROM of right side bending increased from 5% with pain to 50% without any pain. Segmental movement of L1-5 improved and patient no longer had pain bending over. Worst pain decreased from 4/10 to 0/10, present pain decreased from 2/10 to 0/10 and best pain remained at 0/10.

3.2. Patient Two

3.2.1. Evaluation

Patient was a 39-year-old female who presented to physical therapy with the chief complaint of burning and itching along the vulva between the glans of clitoris and the urethral meatus. This pain occurred after her menstrual cycle and lasted for two weeks. She also complained of feeling that her bladder was low and heavy. She had right leg pain and acid reflux. Her treating diagnoses were pelvic wasting and disuse atrophy, unspecified vulvodynia and right leg pain. Her PMH was mitral valve prolapse, vaginal birth with second degree tear for first child and vaginal birth with only one stitch for second child. She did bleed for seven weeks after the last delivery. Bladder and bowel history were positive for cystocele and rectocele. Medications at evaluation were Metoprolol, Prilosec, and a vaginal steroid cream for inflammation. Bladder habits

included incomplete emptying, leaning forward to empty, urination every two to 3 h, nocturia one time per night, and post-void dribble. Bowel habits included urge delay of only 5 min, frequency of once every four to five days, used the squatty potty, stool type four on Bristol Stool Scale, and occasionally used Miralax in her decaffeinated coffee but not on regular basis. She reported pain in the vulvar tissue between urethral meatus and glans of clitoris which was described as an intermittent burning and itching sensation. She also reported introital pain which was described as an intermittent swollen and pressure feeling. Her pain increased with bending, during the afternoon and evening, with urination, and with light menstrual bleeding. Pain assessed on a VAS was best pain 0/10, present pain 4/10 and worst pain 8/10. Socially the pain stopped her from going places. Patient's perceived severity of the problem was 7/10. Objectively she presented with restricted fascia in the lower abdomen and the posterior/medial aspect of her right knee. DRA measurements were two finger-widths above umbilicus, three finger-widths at umbilicus, one finger-width below umbilicus. Musculoskeletal findings included forward head, decreased lordosis, right innominate higher in standing, forward shoulders, posterior pelvic tilt, right shoulder depressed, pes planus, increased weight bearing on left side and medially rotated right innominate. External perineal examination revealed erythema and irritation at vulvar tissues between urethral meatus and glans of clitoris, posterior fourchette scar restricted, visible lift with pelvic contraction, bulge with Valsalva, pain to palpation of vulvar tissues between urethral meatus and glans of clitoris. Internal vaginal exam revealed underactive urogenital triangle (UGT) and levator ani (LA), restricted perineal body, LA strength was 2/5 (as measured with the modified Oxford scale), for 6 s for two reps, UGT endurance was five reps, isolated elongation with bearing down, anterior vaginal wall descent at hymen and posterior vaginal wall descent above hymen with Valsalva in supine position, minimal resting tone of the introitus and laxity of vaginal walls.

3.2.2. Interventions

Visit One (Evaluation): VM consisting of mobility of the root of jejunioileum, mesentery of jejunioileum, loops of jejunioileum, and motility of the jejunioileum.

Visit Two: VM consisting of mobility of the root of the jejunioileum, mesentery of jejunioileum, loops of jejunioileum, and motility of the jejunioileum; sacroiliac joint (SI) correction and instructions on lifting mechanics.

Visit Three: VM consisting of mobility of the root of jejunioileum, mesentery of jejunioileum, loops of jejunioileum, liver, stomach and motility of the jejunioileum, liver and stomach.

Visit Four: VM consisting of mobility of the gallbladder system and greater duodenal papilla, and motility of the gallbladder.

Visit Five: VM consisting of mobility and motility of the liver and stomach.

Visit Six: VM consisting of mobility and motility of the sigmoid colon and bladder.

Visit Seven: VM consisting of mobility of the root of jejunioileum, mesentery of jejunioileum, loops of jejunioileum, abdominal sphincters and motility of the jejunioileum; manual techniques for abdominal fascial stretching and SI correction and exercises for bilateral hip ROM.

Visit Eight: VM consisting of mobility of the abdominal sphincters, exercises for pelvic self-correction and diaphragmatic breathing.

Visit Nine: VM consisting of motility of the liver, gallbladder, and stomach; lifting mechanics; exercises for diaphragmatic breathing and bilateral hip ROM and manual therapy for bowel stimulation and lymph drainage.

Visit Ten: VM consisting of mobility of the abdominal sphincters, lifting mechanics, constipation care education; manual therapy for bowel stimulation, lymph drainage, and myofascial release of the abdomen.

Visit Eleven: VM consisting of mobility of the liver, hepatic flexure, splenic flexure, abdominal sphincters, motility of the liver and large intestine and internal vaginal releases.

Visit Twelve (Discharge): VM consisting of mobility of the root of jejunioileum, mesentery of jejunioileum, loops of jejunioileum, abdominal sphincters, motility of the jejunioileum and manual therapy for SI correction.

3.2.3. Discharge

Patient received 12 sessions of physical therapy over 36 weeks. Complete bladder emptying improved from 0% to 80% of the time. Nocturia improved from one to zero but, increased to one during menstruation. She no longer had pain when urine touched her vulvar tissues. She no longer had post void dribble. Bowel movements improved from once every four to five days to once a day and she continued to use the squatty potty. She no longer had intermittent burning and itching to her urethral meatus or clitoris. She continued to feel swollen at introitus during ovulation. She no longer had pain with urination and bending. Her worst pain decreased from 8/10 to 0/10, present pain decreased from 4/10 to 0/10 and best pain remained at 0/10. DRA decreased from two finger-widths to zero finger-widths above the umbilicus, three finger-widths to one and one-half finger-widths at the umbilicus and one finger-width to zero finger-widths below the umbilicus. UGT endurance improved from five reps to 15 reps. LA strength improved from 2/5 for 6 s for two reps to 3/5 for 10 s for ten repetitions. Posterior vaginal wall descent above hymen and anterior vaginal wall descent at hymen with Valsalva was still present. Her cervix was palpable during ovulation. She no longer had tender points with palpation to internal vaginal structures or externally along the vulvar tissues.

3.3. Patient Three

3.3.1. Evaluation

Patient was a 33-year-old female, who presented to physical therapy with chief complaint of DRA since her first pregnancy two years ago. The DRA worsened with her second baby which was born three months ago. Her treating diagnosis was DRA. She had a medical history of an umbilical hernia. She was gravida two, parous two with greater than 40 hours labor with the first birth. She reported constipation and urinary incontinence. She strained with bowel movements, had limited tolerance for mothering and household activities including lifting, carrying, bending, and cleaning tasks. Her pain included achiness in the back that was intermittent and increased with lifting, carrying, bending, and front carrying of baby. She had occasional sharp abdominal pain in lower abdomen. Pain assessed on a VAS was worst pain 5/10, present and best pain was 0/10. Objectively she presented with lumbar AROM flexion 50%, extension 70%, hypermobility L3 on L4 and anterior shear in standing, anterior pelvic tilt, increased lumbar lordosis, hypertonic lumbar extensors, right iliac crest elevated. She had decreased abdominal tone, tenderness at L3, restrictions of mesenteric root of jejunioileum. DRA before treatment on evaluation date was three and one-half finger-widths above the umbilicus, four and one-half finger-widths at the umbilicus and two finger-widths below the umbilicus. Umbilical hernia was palpable.

3.3.2. Intervention

Visit One (Evaluation): VM consisting of mobility of the root of jejunioleum, mesentery of jejunioleum, loops of jejunioleum and motility of the jejunioleum; anatomy and lifting/carrying ergonomics education.

Visit Two: VM consisting of mobility to the root of jejunioleum, mesentery of jejunioleum, loops of jejunioleum, motility of the jejunioleum and manual therapy to umbilical hernia.

Visit Three: VM consisting of mobility of the root of jejunioleum, mesentery of jejunioleum, loops of jejunioleum; motility of the jejunioleum and manual therapy to umbilical hernia.

Visit Four: VM consisting of mobility of the root of jejunioleum, mesentery of jejunioleum, loops of jejunioleum; motility of the jejunioleum; manual therapy to umbilical hernia and exercise to pelvic floor muscles for quick and long contractions.

Visit Five: VM consisting of mobility of the right kidney and motility of the kidneys; exercises for pelvic floor muscle quick and endurance contractions and transverse abdominis exercises in supine and manual therapy for umbilical hernia and right iliosacral ligament.

Visit Six (Discharge) VM consisting of mobility of the root of jejunioleum, mesentery of jejunioleum, loops of jejunioleum; motility of the jejunioleum and manual therapy for umbilical hernia

3.3.3. Discharge

Patient had six sessions of physical therapy over 26 weeks. Patient had decreased straining with defecation by at least 50%. Low back and abdominal pain were also decreased. Worst pain decreased from 5/10 to 0/10, best and present pain remained 0/10. Functionally she no longer had pain with lifting, carrying, bending and front carry of baby. DRA improved from three and one-half finger-widths to one finger-width above umbilicus, four and one-half finger-widths to two finger-widths at umbilicus and two finger-widths to one finger-width below umbilicus. Her umbilical hernia was still present but not as tender to palpation. Lumbar flexion increased from 50% to 90%. Lumbar extension increased from 70% to 90%.

3.4. Visceral manipulation

In the first four sessions, all three patients received VM techniques of the jejunioleum, as taught by the Barral Institute in the VM1: Abdomen course (Barral and Mercier, 2005; Barral et al., 2013). Each technique is pictured below on a person and directly on a donor's jejunioleum. The techniques were performed in the following order: manipulation of the mesenteric root (Fig. 2 and Videos 1, 2 and 3), manipulation of the loops of the jejunioleum (Fig. 3 and Video 4), manipulation of the mesentery of the jejunioleum (Fig. 4 and Video 5), and motility of the jejunioleum (Fig. 5 and Video 6).

Supplementary video related to this article can be found at <https://doi.org/10.1016/j.jbmt.2020.06.007>

3.5. Outcomes

Tables 1–3 summarize the pre-treatment and post-treatment findings of the three patients. The post-treatment findings reflect not only VM treatments but also other patient specific interventions. The decrease in the IRD that occurred within the first two to four sessions with the use of VM may have impacted the post-treatment findings.

The following graphs (Figs. 6–8) depict DRA finger-width

measurements of the three patients. Measurements were taken at three locations, three-finger widths above the umbilicus, at the umbilicus, and three-finger widths below the umbilicus. The graphs contain measurements from six treatment sessions and illustrate the stabilization of the measurements after the fourth treatment.

4. Discussion

Improvements in DRA finger-width measurements occurred at all sites for all patients over four treatment sessions and were sustained through last follow-up at one year and four months for Patient One, eight months for Patient Two, and six months for Patient Three. All patients received VM during the first four sessions and the most common structure treated with VM was the jejunioleum. When there was a different structure treated with VM, that structure still anatomically connected with the parietal peritoneum and thus the parietal peritoneum could have positively been affected by that treatment. Patients had a decrease in their symptoms and an increase in overall function. In all three cases pain and impairment of functional activities improved with treatment. Only one case had an initial complaint of bladder symptoms and two cases had initial complaints of bowel symptoms. Patient Three had an umbilical hernia, which may have contributed to her more unstable DRA closure.

The authors have formulated anatomical and physiological hypotheses of why DRA may be occurring and how VM of the parietal peritoneum and specifically the jejunioleum may reduce it. Pregnancy may create a restriction in the posterior parietal peritoneum and/or the jejunioleum. This could occur because the expanding uterus creates compressive forces on the viscera. Also, tensile forces could occur on the posterior parietal peritoneum as the uterus expands and the parietal peritoneum moves with it. The uterus is subperitoneal, so as the uterus expands it would displace the parietal peritoneum and jejunioleum in a superior direction creating a mechanical stress in these structures. With the later hypothesis, tensile forces could create isometric strain on the parietal peritoneum and specifically the jejunioleum. Two research studies have shown that isometric strain induces an increase in fascial stiffness (Schlep et al., 2012; Yahia et al., 1993). A restriction anywhere along the posterior parietal peritoneum may pull the anterior parietal peritoneum and all of the abdominal wall layers laterally and posteriorly. This may contribute to the DRA.

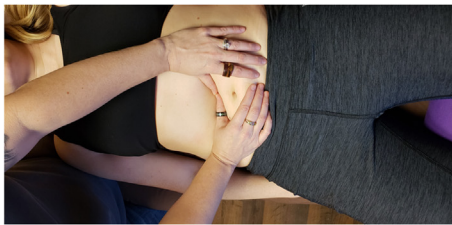
A possible anatomical explanation of the changes in DRA measurements is apparent during fresh cadaver dissections without formaldehyde. Many anatomy texts depict the layers of the abdomen as separate structures. However, during these dissections, it was observed that the abdominal layers of muscle, fascia and parietal peritoneum are not separate from each other. The layers in anterior to posterior order are epidermal layer, dermal layer, subcutaneous fat, anterior rectus abdominis fascia, rectus abdominis muscle, posterior rectus abdominis fascia, anterior transverse abdominis fascia, transverse abdominis muscle, posterior transverse abdominis fascia, anterior parietal peritoneum, intraperitoneal organs covered by visceral peritoneum, posterior parietal peritoneum and retroperitoneal organs. Each layer is attached to the layer posterior to it. For example, the posterior transverse abdominis fascia is attached to the anterior parietal peritoneum. The parietal peritoneum, a serous membrane, is the inner most layer. The parietal peritoneum secretes serous fluids that lubricate organs. The water balloon model can assist in the understanding of the parietal peritoneum. The anterior parietal peritoneum is the front of the balloon and the posterior parietal peritoneum is the back of the balloon. There are organs/structures such as the stomach, gallbladder, and jejunioleum that are intraperitoneal,

meaning inside the peritoneum or the balloon. There are organs/structures such as the kidneys and the pancreas that are retroperitoneal, meaning behind the peritoneum or the balloon. The mesenteric root of the jejunioileum is where the posterior parietal peritoneum (back of the balloon) thickens from the ileocecal valve to the duodenojejunal junction. The root is just anterior to the abdominal aorta, inferior vena cava, right ureter, right ovarian/testicular artery/vein and right psoas. The mesenteric root provides a protected space for the opening through which the mesenteric artery and vein travel from the abdominal aorta/inferior vena cava. These vessels run from retroperitoneal (behind the balloon) to intraperitoneal (inside the balloon) to provide blood flow to and from the jejunioileum. The posterior parietal peritoneum then continues from the root as the mesentery of the jejunioileum, which is like a sling that allows movement. The mesentery slings around the loops of the jejunioileum and attaches it to the posterior parietal peritoneum at the level of the root of the jejunioileum. The mesentery encases the mesenteric artery and vein. The mesenteric root of the jejunioileum is thickened posterior parietal peritoneum and the mesentery of the jejunioileum is also an extension of the posterior parietal peritoneum. These structures are the most posterior


aspects of the parietal peritoneum and thus if all the layers are attached to each other and VM is performed to the posterior parietal peritoneum and specifically its continuation into the jejunioileum, this could create flexibility in that tissue and allow for the more anterior structures like the rectus abdominus bellies to return to their normal resting position.

A possible physiological explanation of the changes in DRA measurements comes from Architecture of Human Living Fascia by Jean-Claude Guimberteau and Armstrong (2015) which states that groups of cells with specific, specialized physiological functions are assembled within a multifibrillar network to form the organs. The cells are embedded in and supported by the fibrillar framework. This basic architectural pattern is the same for all the organs, as well as for the skin, fat, muscles, bones, tendons, nerves and vessels (Guimberteau and Armstrong, 2015). Guimberteau and Armstrong pose the following question, 'Can nature restore harmony to the multifibrillar network when it is subjected to forces that exceed normal physiological limits, as in pathology, or as a result of trauma?' (Guimberteau and Armstrong, 2015). Their answer is that the mobile, adaptable fibrillar network with its intersecting fibers develops a mechanical harmony that is lost when healthy tissue is

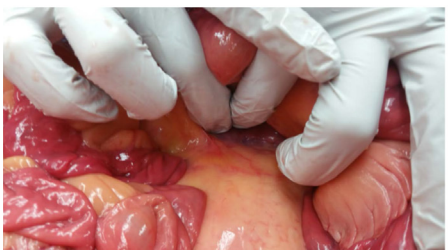
Superior Leaf



Inferior Leaf



Both Leafs Together



Patient Position

- Supine to find the root and its restrictions
- Left side-lying to treat, can treat supine if they can't do this position

Therapist Position

- Standing along patient's right shoulder to find the root and its restrictions
- Standing behind left side-lying patient to treat

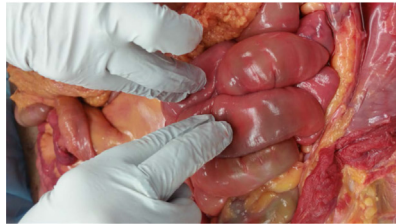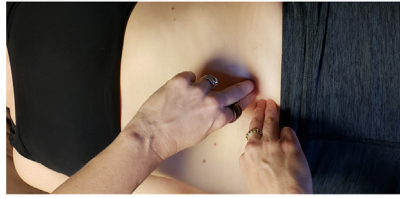
Hand Position

- To find superior leaf: Both thumbs sink posterior/inferior and load perpendicular along a line from the ICV to DJ (feels like a shelf), find most restricted area
- To find inferior leaf: finger-pads of both hands sink posterior/superior and load perpendicular along a line from the ICV to DJ (feels like a shelf), find most restricted area
- Keep thumbs on restricted area of superior leaf and finger-pads on restricted area of inferior leaf and have patient turn onto their left side with their knees bent

Test

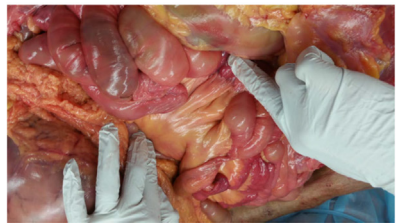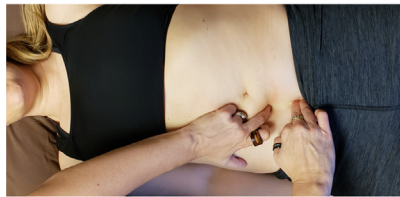
- Superior Leaf: load restricted area perpendicular (towards the table/left side of body) and scoop anterior
- Superior Leaf: Long lever = right shoulder
- Inferior Leaf: load restricted area perpendicular (towards the ceiling/right side of body) and scoop anterior
- Inferior Leaf: Long lever = Right leg: straighten leg back to bring psoas away from root
- If working both leaves together, be gentle, engage, listen and follow

Fig. 2. Manipulation of the mesenteric root of the jejunioileum.



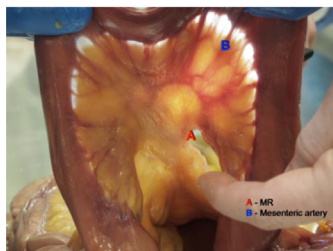- Patient Position**
- Supine
- Therapist Position**
- Standing along patient's right shoulder/ribs
- Hand Position**
- For Motility testing: Both palms lined up with root (ICV to DJ)
 - For Motility testing: Fingers of both hands spread out
 - 2 finger-pads of one hand on restricted area, stay superficial
- Test**
- Motility test to find restricted area: no motion felt in this area
 - This area is usually the same area found with local listening
 - Engage the restricted area with 2 finger-pads of one hand: will feel a listening toward the other loop where tension is located
 - Place 2 finger pads of your other hand on this other loop
- How do they want to communicate?

Fig. 3. Manipulation of the loops of the jejunum.



- Patient Position**
- Supine
- Therapist Position**
- Standing along patient's right shoulder/ribs
- Hand Position**
- Right hand flat along Local Listening area
 - Left finger-pads along restricted area of inferior leaf
- Test**
- Left hand load inferior leaf superiorly, which will cause the restricted loops to pop up into your right monitoring hand
 - Put 2 finger-pads of your right hand on the restricted loops and your left hand remains on the inferior root restriction area
 - Double listen: How do they want to communicate? Listen and follow.
 - Long lever: bent knees rotation left/right

Fig. 4. Manipulation of the mesentery of the jejunum.



- Patient Position**
- Supine
- Therapist Position**
- Standing along patient's right shoulder/ribs
- Hand Position**
- Both palms lined up with root (ICV to DJ)
 - Fingers of both hands spread out, be generous
- Test**
- Connect 20-25 grams (4-5 nickels), VERY LIGHT
 - Be passive with assessing, stay behind the movement, 3.5 seconds each phase

Fig. 5. Motility of the jejunum.

Table 1
Patient one summary of findings pre and post treatment.

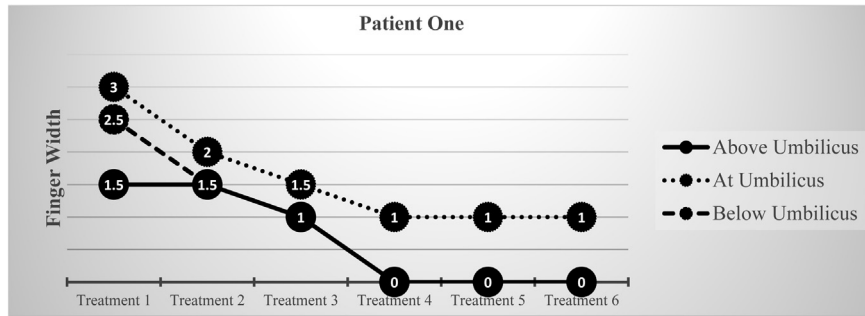
Age	Pre	Post
	37	37
Numeric Pain Rating Scale/Pain Description	<ul style="list-style-type: none"> • Low back = intermittent achiness • Best: 0/10 • Present: 2/10 • Worst: 4/10 	<ul style="list-style-type: none"> • No low back pain/achiness • Best: 0/10 • Present: 0/10 • Worst: 0/10
Bladder Health	<ul style="list-style-type: none"> • Unremarkable 	<ul style="list-style-type: none"> • Unremarkable
Bowel Health	<ul style="list-style-type: none"> • Unremarkable 	<ul style="list-style-type: none"> • Unremarkable
Functional Activities	<ul style="list-style-type: none"> • Difficulty bending over • Back pain with childcare • Difficulty bending to right side 	<ul style="list-style-type: none"> • No difficulty bending over • No back pain with childcare • No difficulty bending to right side
Functional Outcome Scale	<ul style="list-style-type: none"> • Female NIH-Chronic Prostatitis Symptom Index (NIH-CPSI): 0/43 	<ul style="list-style-type: none"> • None conducted
DRA Measurements (in finger-widths)	<ul style="list-style-type: none"> • Above the umbilicus 1.5 • At the umbilicus 3.0 • Below the umbilicus 2.5 	<ul style="list-style-type: none"> • Above the umbilicus 0 • At the umbilicus 1.0 • Below the umbilicus 0
Total Treatment Duration	<ul style="list-style-type: none"> • Seven visits over 18 weeks 	

Table 2
Patient two summary of findings pre and post treatment.

Age	Pre	Post
	39	39
Numeric Pain Rating Scale/Pain Description	<ul style="list-style-type: none"> • Vulvar = intermittent burning/itching • Introitus = intermittent swollen/pressure feeling • Best: 0/10 • Present: 4/10 • Worst: 8/10 	<ul style="list-style-type: none"> • No vulvar burning/itching • Introitus swollen/pressure feeling only during ovulation • Best: 0/10 • Present: 0/10 • Worst: 0/10
Bladder Health	<ul style="list-style-type: none"> • Incomplete emptying • Nocturia, one time per night • Post-void dribble 	<ul style="list-style-type: none"> • Complete emptying 80% time • No nocturia • No post-void dribble
Bowel Health	<ul style="list-style-type: none"> • Dysuria • Once every four to five days • Type 4 on Bristol Stool Scale • Squatty Potty • Occasional Miralax 	<ul style="list-style-type: none"> • No dysuria • Once daily • Type 4 on Bristol Stool Scale • Squatty Potty • Occasional Miralax
Functional Activities	<ul style="list-style-type: none"> • Pain prevents socialization • Difficulty bending • Dysuria • Dysmenorrhea 	<ul style="list-style-type: none"> • No issues with socialization • No difficulty bending • No dysuria • Dysmenorrhea only during ovulation
Functional Outcome Scale	<ul style="list-style-type: none"> • Female NIH-Chronic Prostatitis Symptom Index (NIH-CPSI): 22/43 • Pelvic Floor Disability Index (PFDI-20): 57.13/300 	<ul style="list-style-type: none"> • Female NIH-Chronic Prostatitis Symptom Index (NIH-CPSI): 19/43 • Pelvic Floor Disability Index (PFDI-20): 56.25/300
DRA Measurements (in finger-widths)	<ul style="list-style-type: none"> • Above the umbilicus 2.0 • At the umbilicus 3.0 • Below the umbilicus 1.0 	<ul style="list-style-type: none"> • Above the umbilicus 0 • At the umbilicus 1.5 • Below the umbilicus 0
Total Treatment Duration	<ul style="list-style-type: none"> • 12 visits over 36 weeks 	

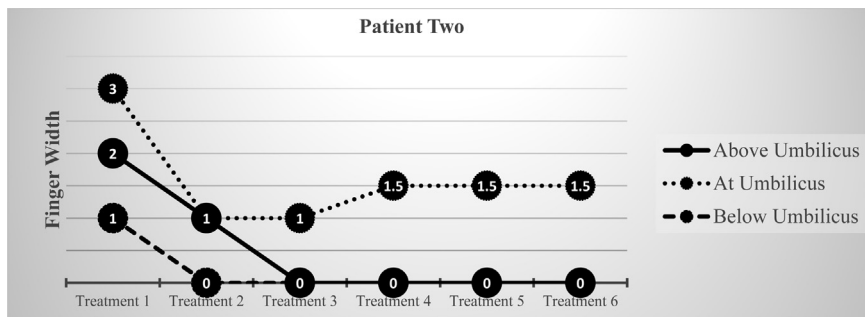
Table 3
Patient three summary of findings pre and post treatment.

Age	Pre	Post
	33	34
Numeric Pain Rating Scale/Pain Description	<ul style="list-style-type: none"> • Low back = intermittent achiness • Lower abdomen = intermittent sharp • Best: 0/10 • Present: 0/10 • Worst: 5/10 	<ul style="list-style-type: none"> • No low back pain • No lower abdomen pain • Best: 0/10 • Present: 0/10 • Worst: 0/10
Bladder Health	<ul style="list-style-type: none"> • Unremarkable 	<ul style="list-style-type: none"> • Unremarkable
Bowel Health	<ul style="list-style-type: none"> • Straining with bowel movements 	<ul style="list-style-type: none"> • Decreased straining with bowel movements by 50%
Functional Activities	<ul style="list-style-type: none"> • Difficulty with childcare • Difficulty with household activities like lifting, carrying, bending, cleaning tasks • Pain with front carry of baby 	<ul style="list-style-type: none"> • No difficulty with childcare • No difficulty with household activities like lifting, carrying, bending, cleaning tasks • No pain with front carry of baby
Functional Outcome Scale	<ul style="list-style-type: none"> • Oswestry Low Back Pain Disability Questionnaire: 8/50 = 16% 	<ul style="list-style-type: none"> • None conducted
DRA Measurements (in finger-widths)	<ul style="list-style-type: none"> • Above the umbilicus 3.5 • At the umbilicus 4.5 • Below the umbilicus 2.0 	<ul style="list-style-type: none"> • Above the umbilicus 1.0 • At the umbilicus 1.5 • Below the umbilicus .5
Total Treatment Duration	<ul style="list-style-type: none"> • Six visits over 26 months 	



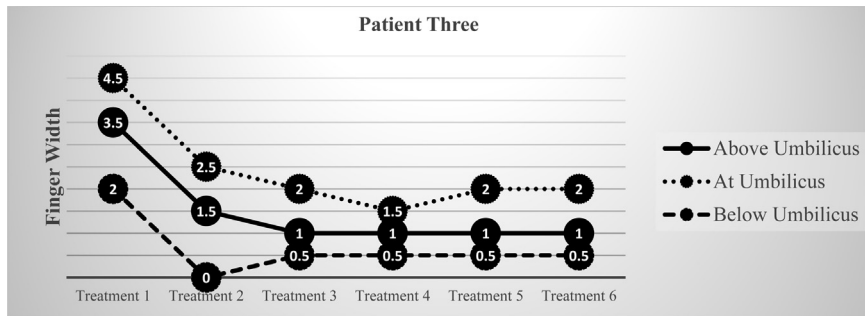
Treatment duration for four treatments was nine weeks.

Fig. 6. Patient one change in DRA measurements.



Treatment duration for four treatments was eight weeks. The measurement at the umbilicus increased from one to one and one-half between treatments three and four. The measurement then stabilized at one and one-half finger-widths.

Fig. 7. Patient two change in DRA measurements.



Treatment duration for four treatments was eight weeks. There was a slight increase in the measurement at the umbilicus from one and one-half to two between treatment four and five. The measurement then stabilized at two finger-widths. Patient’s umbilical hernia may have contributed to this anomaly.

Fig. 8. Patient three change in DRA measurements.

damaged. The body’s repair mechanisms are unable to restore the fibrillar network in the damaged area to its original condition. The replacement tissue is of poor quality, but this can be improved by mobilization of the injured area by manual therapy to enhance the flexibility of the scar tissue (Guimberteau and Armstrong, 2015). In this case study series, the trauma to the tissues was pregnancy. The common manual therapy was VM. The common treated tissue was the parietal peritoneum and specifically its continuation into the root and mesentery of the jejunioileum. In the cases described here, VM may assist by increasing the flexibility along the parietal peritoneum and specifically the jejunioileum, thus allowing the parietal peritoneum and abdominal musculature to return to their normal resting position.

There are several limitations to this case series. One limitation is the small number of reported cases. Another limitation is the retrospective study design. When retrospectively reviewing patient records there were three patients that solely received VM during the first few treatment sessions. A third limitation is that finger-width measurements were utilized to assess DRA. When comparing ultrasound measurements and finger-width measurements of DRA Mota et al. (2013) concluded that palpation had sufficient reliability to be used in clinical practice, however, ultrasound is more accurate. The fourth limitation was that each patient received additional treatment after the first four treatments which may have influenced the patient outcomes including the sustained DRA measurements. The next step is to perform a study utilizing a

randomized control design incorporating real-time ultrasound measurements of DRA to fully evaluate the effect of VM of the jejunioleum on DRA.

5. Summary

After four treatments of VM, with the most common structure treated being the jejunioleum, three patients reported functional improvements with objective changes noted in DRA measurements. Additional interventions were given and the changes in the DRA measurements remained stable until discharge, which ranged from six to eleven months. It is possible that VM can positively impact DRA.

Clinical relevance

- Dysfunction in the parietal peritoneum may contribute to a DRA.
- VM, specifically of the jejunioleum, may decrease the IRD of a DRA.

Funding

This research did not receive any specific grant from funding agencies in the public, commercial, or not-for-profit sectors.

Declaration of competing interest

1. Teresa Elliott-Burke – Declarations of Interest: none
2. Brandi Kirk – Declarations of Interest: instructor for the Barral Institute

CRedit authorship contribution statement

Brandi Kirk: Conceptualization, Writing - review & editing, Visualization. **Teresa Elliott-Burke:** Methodology, Resources, Writing - original draft, Supervision.

Acknowledgement

The authors wish to thank the individuals who donated their bodies and tissues for the advancement of education and research.

References

Archambault-Ezenwa, L., Brewer, J., Markowski, A., 2016. A comprehensive physical therapy approach including visceral manipulation after failed biofeedback therapy for constipation. *Tech. Coloproctol.* 20, 603–607. <https://doi.org/10.1007/s10151-016-1489-4>.

Barral, J.P., Mercier, P., 2005. *Visceral Manipulation*, Revised ed. Eastland Press, Seattle.

Barral, J.P., Polec, L., Grant, L., Wetzler, G., 2013. *Visceral Manipulation: Abdomen 1 Study Guide (VM1)*.

Benjamin, D.R., Van de Water, A.T.M., Peiris, C.L., 2014. Effects of exercise on diastasis of the rectus abdominis muscle in the antenatal and postnatal periods: a systematic review. *Physiotherapy* 100 (1), 1–8. <https://doi.org/10.1016/j.physio.2013.08.005>.

Bowe, G.M., Chapelle, S.L., 2012. Visceral mobilization can lyse and prevent peritoneal adhesions in a rat model. *J. Bodyw. Mov. Ther.* 16, 76–82. <https://doi.org/10.1016/j.jbmt.2011.02.004>.

Brauman, D., 2008. Diastasis recti: clinical anatomy. *Plast. Reconstr. Surg.* 122 (5), 1564–1569. <https://doi.org/10.1097/PRS.0b013e3181882493>.

Chiarello, C., Falzone, L., McCaslin, K., Patel, M., Ulrey, K., 2005. The effects of an exercise program on diastasis recti abdominis in pregnant women. *J. Women's Health Phys. Ther.* 29 (1), 11–16.

Dufour, S., Bernard, S., Murray-Davis, B., Graham, N., 2019. Establishing expert-based recommendations for the conservative management of pregnancy-related diastasis rectus abdominis: a delphi consensus study. *J. Women's Health Phys. Ther.* 43 (2), 73–81. <https://doi.org/10.1097/JWH.0000000000000130>.

Guimberteau, J.C., Armstrong, C., 2015. *Architecture of Human Living Fascia: the Extracellular Matrix and Cells Revealed through Endoscopy*. Handspring Publishing, Pencaitland, Scotland.

Irion, J., Irion, G., 2010. *Women's Health in Physical Therapy*. Lippincott Williams & Wilkin, Baltimore, MA.

Keeler, J., Albrecht, M., Eberhart, L., Horn, L., Donnelly, C., Lowe, D., 2012. Diastasis recti abdominis: a survey of women's health specialist for current physical therapy clinical practice for postpartum women. *J. Women's Health Phys. Ther.* 36, 131–142. <https://doi.org/10.1097/JWH.0b013e318276f35f>.

Lee, D., 2017. *Diastasis Recti Abdominis – A Clinical Guide for Those Who Are Split Down the Middle*. Learn with Diane Lee. Surrey, BC, Canada.

Lee, D.G., Lee, L.J., McLaughlin, L., 2008. Stability, continence and breathing: the role of fascia following pregnancy and delivery. *J. Bodyw. Mov. Ther.* 12, 333–348. <https://doi.org/10.1016/j.jbmt.2008.05.003>.

Liaw, L., Hsu, M., Liao, C., Liu, M., Hsu, A., 2011. The relationship between inter-recti distance measured by ultrasound imaging and abdominal muscle function in postpartum women: a 6-month follow-up study. *J. Orthop. Sports Phys. Ther.* 41 (6), 435–443. <https://doi.org/10.2519/jospt.2011.3507>.

Mahalaskhmi, V., Sumathi, G., Shitra, T.V., Ramamoorthy, V., 2016. Effect of exercise on diastasis recti abdominis among the primiparous women: a quasi-experimental study. *Int. J. Reprod. Contracept. Obstet. Gynecol.* 5 (12), 441–444. <https://doi.org/10.18203/2320-1770.ijrcog20164360>.

McSweeney, T.P., Ost, M., Thompson, O.P., Johnston, R., 2012. The immediate effects of sigmoid colon manipulation on pressure pain thresholds in the lumbar spine. *J. Bodyw. Mov. Ther.* 16, 416–423. <https://doi.org/10.1016/j.jbmt.2012.02.004>.

Mota, P., Pascoal, A., Carita, A., Bo, K., 2015. Prevalence and risk factor of diastasis recti abdominis from late pregnancy to 6 months postpartum, and relationship with lumbo-pelvic pain. *Man. Ther.* 20, 200–205. <https://doi.org/10.1016/j.math.2014.09.002>.

Mota, P., Pascoal, A.G., Sancho, F., Carita, A.I., Bo, K., 2013. Reliability of the inter-rectus distance measure by palpation. Comparison of palpation and ultrasound measurements. *Man. Ther.* 18, 294–298. <https://doi.org/10.1016/j.math.2012.10.013>.

Parker, M., Millar, L., Dugan, S., 2008. Diastasis rectus abdominis and lumbo-pelvic pain and dysfunction-are they related. *J. Women's Health Phys. Ther.* 32, 15–22.

Schlep, R., Duersele, L., Vleeming, A., Naylor, I.L., Lehmann-Horn, F., Zorn, A., Jaegar, H., Klingler, W., 2012. Strain hardening of fascia: static stretching of dense fibrous connective tissues can induce temporary stiffness increase accompanied by enhanced matrix hydration. *J. Body Works Mov. Ther.* 16, 94–100. <https://doi.org/10.1016/j.jbmt.2011.09.003>.

Sperstad, J.B., Tennifjord, M.K., Hilde, G., Ellstron-Eng, M., Bo, K., 2016. Diastasis recti abdominis during pregnancy and 12 months after childbirth: prevalence, risk factors and reports of lumbopelvic pain. *Br. J. Sports Med.* 50, 1092–1096. <https://doi.org/10.1136/bjsports-2016-096065>.

Spitznagle, T., Leong, F.C., Van Dillen, L.R., 2007. Prevalence of diastasis recti abdominis in a urogynecological patient population. *Int. Urogynecol. J.* 18, 321–328. <https://doi.org/10.1007/s00192-006-0143-5>.

Tuttle, L., Fasching, J., Keller, A., Patel, M., Saville, C., Schlaff, R., Walker, A., Mason, M., Gombatto, S.P., 2018. Noninvasive treatment of postpartum diastasis recti abdominis: a pilot study. *J. Women's Health Phys. Ther.* 42 (2), 65–75. <https://doi.org/10.1097/JWH.0000000000000101>.

Wetzler, G., Roland, M., Fryer-Dietz, S., Dettmann-Ahern, D., 2017. Craniosacral therapy and visceral manipulation: a new treatment intervention for concussion recovery. *Med. Acupunct.* 29 (4), 239–248. <https://doi.org/10.1089/acu.2017.1222>.

Yahia, L.H., Pigeon, P., DesRosiers, E.A., 1993. Viscoelastic properties of the human lumbodorsal fascia. *J. Biomed. Eng.* 15, 425–429.

Zappile-Lucis, M., 2009. Quality of life measurements and physical therapy management of a female diagnosed with diastasis recti abdominis. *J. Women's Health Phys. Ther.* 33, 22.

Zollars, J.A., Armstrong, M., Whisler, S., Williamson, S., 2019. Visceral and neural manipulation in children with cerebral palsy and chronic constipation: five case reports. *Explore* 15 (1), 47–54. <https://doi.org/10.1016/j.explore.2018.09.001>.