



Clinical. Lactation



Official Journal of the
United States Lactation Consultant Association

IBCLCs and Craniosacral Therapists

Strange Bedfellows or a Perfect Match?

Patricia Berg-Drazin, IBCLC, RLC, CST¹

Share this:



The rate of ankyloglossia (tongue-tie) appears to be on the rise in the United States and around the world. IBCLCs working with the families of babies with tongue-tie all too often are the first ones to notice the symptoms and suggest treatment. Even after the tongue has been released, these infants continue to struggle with breastfeeding. The tongue plays an integral role in breastfeeding, but it is also crucial to other oral functions such as speech, respiration, oral hygiene, swallowing, and chewing. The tongue is connected through the extrinsic muscles to bone both above and below the oral cavity. The restriction of the tongue results in associated strains in the body. We will follow the muscular connections and origins to understand the influences in the body. Craniosacral therapy (CST) has its origin in osteopathy, which teaches that structure and function are reciprocally interrelated. When structure is compromised, function will be as well. CST is a perfect complement to help these infants' bodies release the tensions created as well as to aid in rebalancing structurally and somatically. A case study will illuminate the tremendous impact CST can have on children suffering from tongue-tie.

Keywords: ankyloglossia, tongue-tie, lactation, breastfeeding, craniosacral therapy

Health organizations worldwide unanimously agree that breastfeeding is the best source of nutrition for the optimal health, development, and growth of an infant (Academy of Breastfeeding Medicine, 2008; American Academy of Family Physicians, 2012; American Academy of Pediatrics, 2012; United Nations Children's Emergency Fund, 2014; World Health Organization, 2015). They all recommend breastmilk as the sole source of nutrition for the first 6 months of life.

Ankyloglossia, more commonly known as tongue-tie, can cause breastfeeding difficulties or a cessation of breastfeeding. Mothers of babies with ankyloglossia experience similar difficulties as mothers who wean prematurely. These difficulties include, but are not limited to, sore, cracked, and/or bleeding nipples; engorgement; recurrent plugged ducts; mastitis; breast abscess; poor milk supply; an unsettled baby; frequent feeds; and faltering growth (Ballard, Auer, & Khoury, 2002; Buryk, Bloom, & Shope, 2011; Fernando, 1998; Finigan & Long, 2013; Geddes et al., 2008; Griffiths, 2004; Masaitis & Kaempf, 1996; McAndrew et al., 2012; Messner, Lalakea, Aby, Macmahon, & Bair, 2000; Praborini, Purnamasari, Munandar, & Wulandari, 2015; Ricke, Baker, Madlon-Kay, & DeFor, 2005; Todd, 2014; Todd & Hogan, 2015). It has been reported that ankyloglossia has resulted in babies consuming insufficient breastmilk resulting in failure to thrive (Ballard et al., 2002; Forlenza, Black,

McNamara, & Sullivan, 2010; A. Velasco, personal communication, May 7, 2014).

The diminished range of motion stemming from tongue-tie has been implicated in dysfunctions ranging from a high-arched palate, problems with swallowing, malocclusion, articulation in speech, oral motor dysfunctions, oral-facial structure mobility, uncontrollable salivation, and an inability to perform dental hygiene later on in life (Cockley & Lehman, 2015; Defabianis, 2000; Fernando, 1998; Haham, Marom, Mangel, Botzer, & Dolberg, 2014; Hall & Renfrew, 2005; Hazelbaker, 2010; Kupietzky & Botzer, 2005; Medeiros, Ferreira, & Felicio, 2009; Meenakshi & Jagannathan, 2014; Praborini et al., 2015; Walls et al., 2014; Watson-Genna, 2013).

There is muscular tension that accompanies tongue-tie, which is frequently not released when the tongue-tie is revised. Infants experiencing feeding difficulties may become stressed. The sympathetic nervous system can go into overdrive (Fernando, 1998). Professional experience and shared cases suggest that craniosacral therapy (CST) can be effective in both releasing the tension that remains after the tongue-tie is released as well restoring the central nervous system to optimal performance (Jones & Prasaka, 2014; Kotlow, 2015; Wanveer, 2009).

Tongue-tie and the treatment thereof are not a new phenomenon. In the King James Version Bible—Mark 7:35:

And the string of his tongue was loosed, and he spake plain.

1. patricia@pbdrazin.com

William Moss wrote in his 1794 treatise:

A child's being tongue-tied will impede and hinder his sucking freely. When that happens, he may be observed to lose his hold very often, and, when he draws the breast he frequently makes a clicking noise. Upon this occasion the mouth must be examined and the tongue set at liberty by cutting a ligament or string which will be found to confine the tongue down to the lower part of the mouth.

Statistically speaking, the occurrence of tongue-tie appears to be increasing. In a 1941 study, it was found that 4 in 1,000 infants suffered from ankyloglossia (Fernando, 2015). Studies done between 2000 and 2005 found a range of 3.2%–12.8% of newborns were tongue-tied (Ballard et al., 2002; Dollberg, Marom, & Botzer, 2014; Messner et al., 2000; Praborini et al., 2015; Ricke et al., 2005).

In reality, the rate of occurrence is most likely considerably higher. There is no agreed upon qualitative tool for tongue-tie evaluation. This was demonstrated by Haham et al. (2004) who found that in 200 infants, all but one had either an observable or palpable lingual frenulum using the Coryllos classification (Coryllos, Watson-Genna, & Salloum, 2004). Infants upon birth are not routinely checked for tongue-tie. The Assessment Tool for Lingual Frenulum Function (ATLFF; Hazelbaker, 1993) is the most commonly used evaluation method. Concern has been expressed that the ATLFF contains too many subjective components and lacks inter-rater reliability (McAndrew et al., 2012; Ricke et al., 2005; Rowan-Legg, 2015). Ballard

et al. (2002) discloses that the ATLFF has not been validated in a controlled manner.

The Tongue and Its Connections

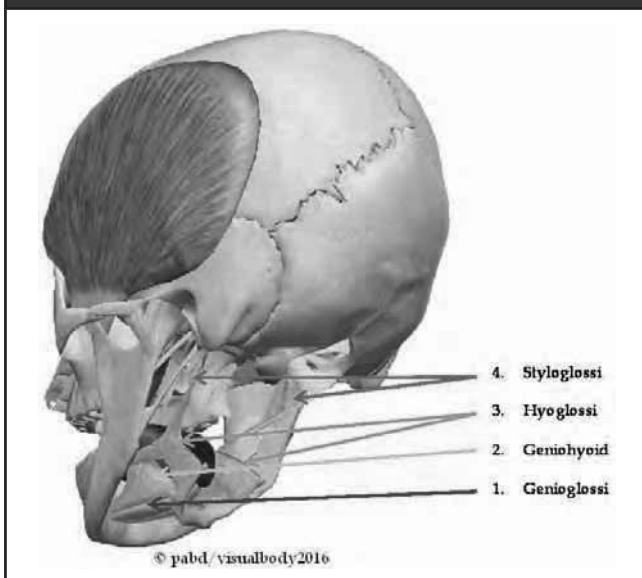
Ankyloglossia comes from the Greek words *agkilos* for crooked or loop and *glossa* for tongue. The frenulum under the tongue is tethering the tongue to the floor of the mouth. This “tether” restricts the tongue’s range of motion and, by extension, restricts the motion of every other muscle or bone that it is attached to. To better understand the etiology of these restrictions, we need to start with an understanding of the anatomy of the tongue and how the tongue relates to the rest of the body.

The tongue is made up of intrinsic and extrinsic muscles. The intrinsic muscles have both their origin and their insertion within the tongue. The extrinsic muscles originate in bones and insert in the tongue. The extrinsic muscles are anchored to bones. We want to look more closely at the extrinsic muscles and follow their paths to understand the strain patterns created.

The extrinsic muscles are the genioglossi, geniohyoid, hyoglossi, styloglossi, and the mylohyoid (Figures 1 and 2; Table 1).

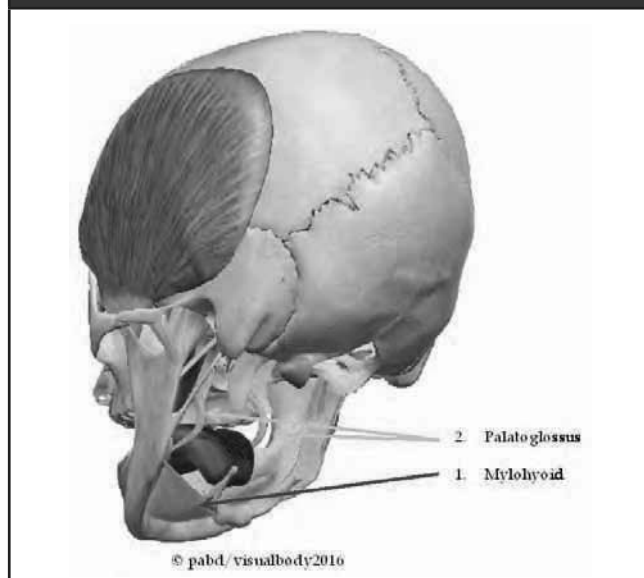
One additional muscle of importance to us is the palatoglossus. The palatoglossus muscle forms the anterior portion of the arch from which the uvula hangs. From the undersurface of the soft palate, the palatoglossus curves downward and inserts into the side of the tongue. Tension on this muscle created

Figure 1. Extrinsic muscles of the tongue.



Note. Photo used with permission.

Figure 2. Extrinsic muscle and palatoglossus.



Note. Photo used with permission.

Table 1. Figures 1 and 2

Muscle	Origin	Insertion	Figure
Genioglossi	Mental spine of the mandible	Length of the tongue	1-1
Geniohyoid	Mental spine of the mandible	Superior body of the hyoid	1-2
Hyoglossi	Greater horn of the hyoid	Lateral surface of the tongue	1-3
Styloglossi	Anterior and lateral surface of the styloid process near its apex	Lateral surface of the tongue	1-4
Mylohyoid	Mandible	Hyoid	2-1
Palatoglossus	Palatine aponeurosis	Posterolateral tongue	2-2

by a tongue-tie may be a contributory factor in the high palate often seen with tongue-tied individuals (Figure 2; Table 1).

There are some common areas of tension seen in babies with ankyloglossia that may be explained by looking at this musculature.

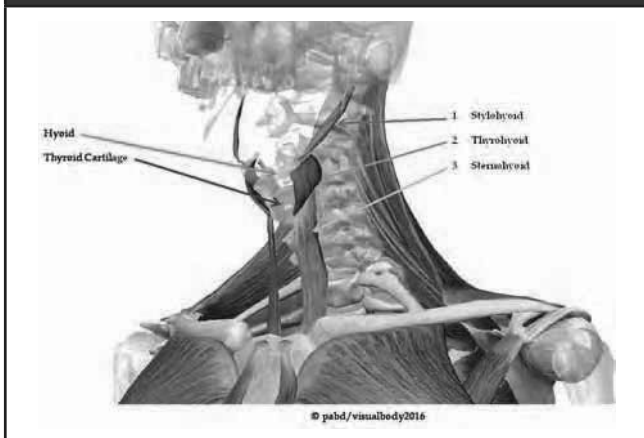
The mandible of a baby with ankyloglossia maybe retracted more than “normal” for a newborn—the genioglossus and geniohyoid originating from the inside surface of the mandible and inserting along the entire length of the tongue could pull the mandible posteriorly (toward the back). The retraction of the mandible can impede effective milk transfer (see Figure 6; Watson Genna, 2013).

The styloglossi attaches to the styloid process, the styloid process attaches to the temporalis. When the tongue is tethered, the styloglossi will be pulled anteriorly (forward) and inferiorly (downward). This may put tension on the cranium, starting at the styloid process, and may affect the temporal, parietal, and occipital bones. This tension

could be the cause of the chronic headaches that tongue-tied adults have shared experiencing. They often resolve after tongue-tie revision. Infants, if they are having headaches, are unable to communicate that to us.

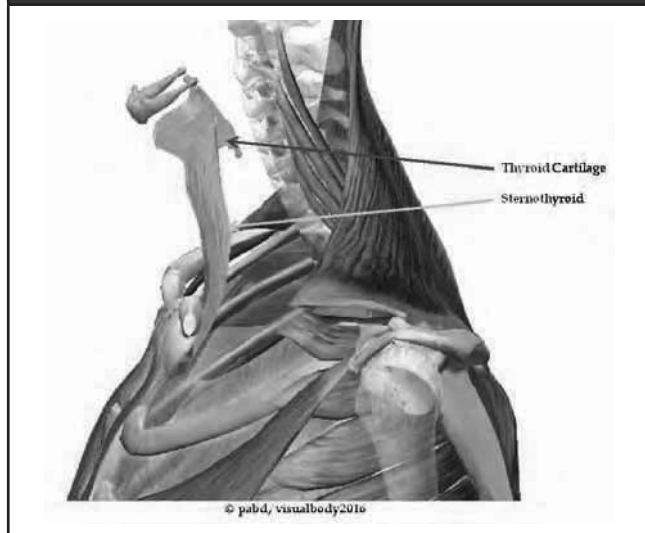
Infants are unable to communicate what hurts, therefore listening to adults sharing their experiences pre and postrevision gives us insight into what infants may be experiencing. Adults have spoken of the elimination of headaches, experiencing greater ability to open their mouths and improved speech. One woman shared that her hip alignment improved (Fetzik, 2014; Morgan, n.d.). Another woman shared her difficulty swallowing prerevision and its improvement after (L. Anderegg, personal communication, October 29, 2014). Recently, several adults, in an adult tongue-tie group, have shared structural changes and greater height measurements posttongue-tie revision. This would follow the strains discussed on the sternum (Figures 3 and 4).

Figure 3. Stylohyoid, Thyrohyoid, and Sternohyoid.



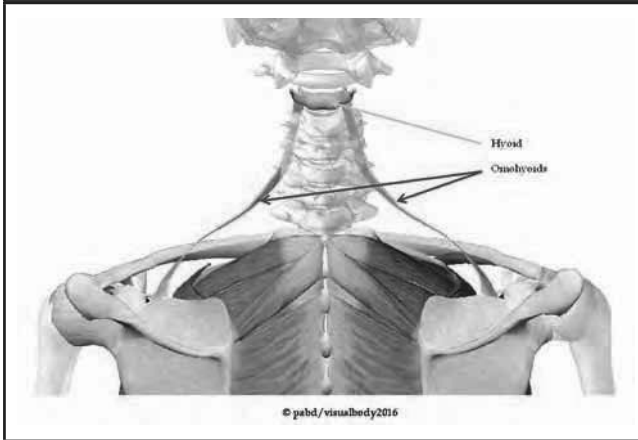
Note. Photo used with permission.

Figure 4. Sternohyoid.



Note. Photo used with permission.

Figure 5. Omohyoid.



Note. Photo used with permission.

The palatoglossus pulling down on the palatines could explain the higher palates that are often seen in tongued-tied infants and adults. Defabianis (2000) published a case report in which, following the revision of the tongue, there was spontaneous expansion of the upper arch. The patient was followed clinically and radiologically for 7 years (Figure 2).

Neck and sternum tension seen in tongued-tied babies follow the restrictions created by the genioglossi, geniohyoid, and hyoglossi on the hyoid. The hyoid bone connects the floor of the oral cavity to the pharynx and larynx. The genioglossi, geniohyoid, and the hyoglossi all attach to the hyoid. If the tongue has no motion, the hyoid will be tethered, as will all of its attachments (Figure 3; Table 1).

The next step in this process is to look at the muscles that attach to the hyoid and trace them. These are the stylohyoid, thyrohyoid, sternohyoids, sternothyroid, and omohyoids (Figures 3, 4 and 5; Table 2).

Structural observations of infants at rest with ankyloglossia include thoracic tension, raised arms, and hips in

flexion (see below). Osteopathy teaches that structure and function are reciprocally interrelated. When structure is compromised, function is compromised (see Figures 6–8).

Following the musculature and looking at the infant depicted in Figure 7, you can see how the restrictions of the tongue travel down the body.

The stylohyoid pulls from the styloid process to the hyoid, the sternohyoids pulls from the hyoid to the sternum (Figures 3 and 4).

The thyrohyoid pulls from the hyoid to the thyroid cartilage, the sternothyroid pulls from the thyroid cartilage to the sternum (Figure 3; Table 2).

The omohyoids are pulling on the scapula. The arm raising may help relieve some of the tension created by the omohyoids. (Figure 5; Table 2)

Releasing the restriction on the tongue does not necessarily translate to the other muscles that are holding tension. Both the neural and the muscular components need to be educated into correct firing and movement patterns. This is where CST can be advantageous.

What Is Craniosacral Therapy?

CST has its origin in osteopathic medicine. It started with Andrew Still. As was common in the 1890s, Andrew apprenticed with his father, a physician, and followed in his father’s footsteps. Andrew lost his first wife, Mary, to childbirth complications. Not long after, he lost three of his children to meningitis, despite the fact that they received the standard care of those times. Andrew’s daughter by his second wife died of pneumonia. Andrew attributed these deaths to the medical practices of the day. This led him to look for alternative ways of treating disease. He investigated hydropathy, diet, bonesetting, homeopathy, and magnetic healing in his search for a way to enhance nature’s own healing abilities.

Table 2. Figures 3, 4, and 5

Muscle	Origin	Insertion	Figure
Stylohyoid	Stylo process	Hyoid	3-1
Thyrohyoid	Thyroid cartilage	Hyoid	3-2
Sternohyoid	Sternum	Hyoid	3-3
Sternothyroid	Sternum	Thyroid cartilage	4-1
Omohyoid	Scapula	Hyoid	5-1

He believed that “rational medical therapy” would one day consist of manipulations of the musculoskeletal system. The key was to find and correct anatomical deviations that interfered with the free flow of the blood and nerve force in the body. To that end, he developed osteopathy and opened the first osteopathic school in 1892.

William Sutherland was a student of Dr. Still. Dr. Still encouraged students to further his explorations and to “keep digging.” Dr. Sutherland was the first person to perceive the movements of the cranial bones. He developed the concept of “primary respiration” to describe the motion created by the cerebral spinal fluid. Dr. Sutherland developed “cranial osteopathy.”

John Upledger, DO, FAAO, took the next step. Dr. Upledger, along with a neurophysiologist and histologist, Ernest W. Retzlaff, researched Dr. Sutherland’s theory of cranial motion and primary respiration. Their published results supported Dr. Sutherland’s theories. Dr. Upledger opened his institute to educate the public and healthcare professionals about the benefits of CST. Dr. Upledger explains CST as “a gentle, hands-on method of evaluating and enhancing the function of the physiological body system called the craniosacral system—compromised of the membranes and the cerebrospinal fluid that surround and protect the brain and the spinal cord. Using a soft touch, generally no greater than 5 grams, or about the weight of a nickel, practitioners release restrictions in the craniosacral system and thereby improve the functioning of the central nervous system. By complementing the body’s natural healing processes, CST is increasingly used as a preventative healthcare measure for its ability to bolster resistance to disease, and is effective for a wide range of medical problems associated with pain and dysfunction (The Upledger Institute, 2011).

Craniosacral Therapy for the Baby With Ankyloglossia

Using the craniosacral system’s motion, the craniosacral therapist can locate areas that are restricted and/or unbalanced because of the strain on the system from the restriction of the tongue. Using very light touch, between zero to one gram for an infant, the craniosacral therapist assists the body in gaining its full range of motion. The body needs a full range of motion for optimal functioning.

CST also helps to balance and give flexibility to the nervous system. The nervous system is made up of the sympathetic and the parasympathetic nervous systems.

The sympathetic nervous system responds to danger, whereas the parasympathetic monitors bodily functions. There are stressors in all of our lives on a regular basis. The sympathetic nervous system is activated with each of these occurrences. Sometimes, the body has difficulty dispersing the accumulated stress. CST can help to restore the nervous system and give it flexibility in order for the system to respond more effectively to stresses and challenges.

Babies go through many transitions which can be extremely stressful in a very short time span. Some manage these transitions (stressors) better than others. After birth, infants have to learn to manage all of the functions that previously have been taken care of for them. Difficulties with sucking, swallowing, breathing, and eating create additional unexpected stressors.

The releasing of the tongue-tie will not necessarily release the musculature that has been restricted because of the tongue-tie. The musculature often needs assistance to know that it is now safe to let go and learn to move as the body intends. The sympathetic nervous system needs assistance dispersing the accumulated stress. This is where CST can play an important role.

Case Study

Baby Jane (fictional name) was born by cesarean section because of a breach presentation. The mother reported that Jane was latching on within an hour of delivery and appeared to be breastfeeding well during their 4-day hospital stay. On Day 5, mother and baby saw their pediatrician who made no mention of a lip or tongue-tie.

They had an IBCLC come to their home the following week because mom was struggling with unresolving engorgement. The IBCLC did not do an intraoral assessment of the infant but told her “everything looked good.”

After another week, mom’s engorgement progressively got worse, and Jane was having difficulty feeding. The IBCLC returned and this time did a before-and-after-feeding weighing. Three ounces were transferred in one feeding. The IBCLC looked in Jane’s mouth and noticed a tongue-tie.

With Jane’s increasing fussiness and difficulty feeding, mom took Jane to another pediatrician who noted a lip-tie and recommended a local dentist who does lip and tongue-tie revisions.

The dentist saw Jane that afternoon. He also noted that there was a tongue-tie. Both were revised. Both were

considered Class 3 using the Coryllos/Watson Genna classification (Coryllos et al., 2004).

Post-revision, the dentist, on hearing her list of difficulties, recommended that mom take Jane to a CST to help work through some of the restrictions and stresses that would remain despite the revision.

Jane saw the craniosacral therapist 24 hours post-revision. Both parents went to the session. They shared with the craniosacral therapist, prior to the session, that Jane was so “tight” that mom was unable to hold and comfort her. She was constantly fussy which was making parenting and breastfeeding difficult. Mom also noticed that Jane preferred laying her head to one side as shown in Figure 8. The omohyoids originate in the scapula and insert into the hyoid. The hyoid is restricted by the tongue-tie. The infant raises her arms to reduce the strain from the tension of the omohyoids (Figures 5 and 8; Table 2).

Some craniosacral therapists start by placing babies on a blanket and sharing with the parents a structural assessment. As seen earlier, the arms are raised, the head turns left—parents may not notice these things or be aware that they are indications of restrictions and tension (Simpson, 2015).

Babies are usually treated on a blanket or on the therapist’s lap. Infant sessions are generally an hour in length. Breaks are taken as needed for feeding and changing.

Figure 6. Infant photo #1.



Note. Photo used with permission.

Figure 7. Infant photo #2.



Note. Photo used with permission.

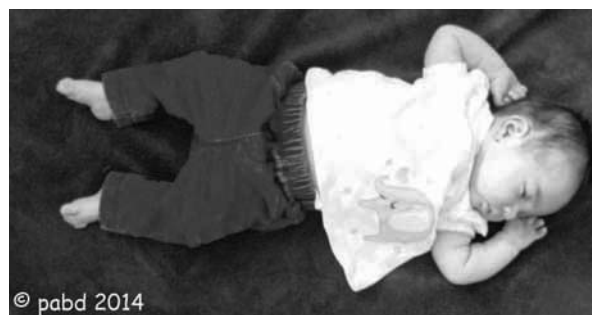There were significant restrictions in the thoracic area as well as across the scapula. When you follow the pathway from the tongue, as discussed earlier, the restriction in the scapula and thoracic area is understandable. There may be other patterns of restriction as well.

When Jane was handed back to her mother post therapy session, Jane “melted” into mom’s chest. Both parents started to cry. Jane’s mother said that this was the first time Jane had melted into her and that she had been able to hold her.

Upon follow-up, mom shared that

when we came home from the craniosacral therapy, things were amazing. Jane was so calm and seemed so happy. It took about 3 days, but she was able to eat on either breast and in whatever position we

Figure 8. Infant photo #3.



Note. Photo used with permission.

wanted. We were normally doing cradle before the pulling away from the breast started to happen. [After the treatment], Jane was doing great; she was far less fussier and was sleeping better at night, too. She also wasn't clenching her arms above her head as much. I [mom] noticed she wasn't always putting her head to the right all the time.

These are tremendous results following one craniosacral session. One cannot expect all babies to experience such an incredible response. It is the author's experience that tremendous results appear to be commonplace following either one or several treatments.

Discussion

The African proverb attributed to Margaret Mead, "it takes a village to raise a child," also should apply to healthcare professionals of different disciplines working together sharing knowledge and skills for the betterment of the child and the family.

The IBCLC assisting struggling new parents are often the first to notice the tongue's restrictions. Parents may then be referred to local dentists; ear, nose, and throat specialists; or other medical professionals who have an understanding of ankyloglossia and are trained in revision (Ballard et al., 2002; Fernando, 1998; Finigan & Long, 2013; Watson Genna, 2002). On recommendation of the lactation consultant or the provider who will be doing the revision, many parents are referred to a craniosacral therapist prior to having the revision done and again after the procedure. We are the village—the IBCLC who helps to uncover the cause of the difficulty, the practitioner who revises, and the craniosacral therapist who, with an understanding that structure and function are reciprocally interrelated, can help the infant's body regain its optimal structure and fluidity of movement. We need to work in concert to raise the next generation so that they can rise to their highest potential.

References

- Academy of Breastfeeding Medicine. (2008). ABM statement: Position on breastfeeding. *Breastfeeding Medicine*, 3(4), 267–270.
- American Academy of Family Physicians. (2012). *Breastfeeding (policy statement)*. Retrieved from <http://www.aafp.org/about/policies/all/breastfeeding.html>
- American Academy of Pediatrics. (2012). Policy statement: Breastfeeding and the use of human milk. *Pediatrics*, 129, e827–e841.
- Ballard, J. L., Auer, C. E. D., & Khoury, J. C. (2002). Ankyloglossia: Assessment, incidence, and effect of frenuloplasty on the breastfeeding dyad. *Pediatrics*, 110(5), e63. Retrieved from <http://www.pediatrics.org/cgi/content/110/5/e63>
- Buryk, M., Bloom, D., & Shope, T. (2011). Efficacy of neonatal release of ankyloglossia: A randomized trial. *Pediatrics*, 128(2), 280–288.
- Cockley, L., & Lehman, A. (2015). The ORTHO missing link: Could it be tied to the tongue? *Journal of the American Orthodontic Society*, 15(1), 18–21.
- Coryllos, E., Watson Genna, C., & Salloum, A. (2004). *Congenital tongue-tie and its impact on breastfeeding*. Elk Grove Village, IL: American Academy of Pediatrics, Section on Breastfeeding.
- Defabianis, P. (2000). Ankyloglossia and its influence on maxillary and mandibular development (A seven-year follow-up case report). *The Functional Orthodontist*, 17(4), 25–33.
- Dollberg, S., Marom, R., & Botzer, E. (2014). Lingual frenotomy for breastfeeding difficulties: A prospective follow-up study. *Breastfeeding Medicine*, 9(6), 286–289.
- Fernando, C. (1998). *Tongue tie—from confusions to clarity: A guide to the diagnosis and treatment of ankyloglossia*. Sydney, Australia: Tandem.
- Fernando, C. (2015). *Tongue tie: Information for parents and practitioners*. Retrieved from Tonguetie.net
- Fetzik, M. (2014). *Celebrating two years migraine free*. Retrieved from <http://www.happykansasfaces.com/blog/archives/09-2014>
- Finigan, V., & Long, T. (2013). The effectiveness of frenulotomy on infant-feeding outcomes: A systematic review. *Evidence Based Midwifery*, 11(2), 40–45.
- Forlenza, G., Black, N., McNamara, E., & Sullivan, S. (2010). Ankyloglossia, exclusive breastfeeding, and failure to thrive. *Pediatrics*, 125(6), e1500–1504. Retrieved from <http://pediatrics.aappublications.org/content/125/6/e1500>
- Geddes, D., Langton, D., Gollow, I., Jacobs, L. A., Hartmann, P., & Simmer, K. (2008). Frenulotomy for breastfeeding infants with ankyloglossia: Effect on milk removal and sucking mechanism as imagined by ultrasound. *Pediatrics*, 122(1), e188–194. Retrieved from http://pediatrics.aappublications.org/content/122/1/e188?sso=1&sso_redirect_count=1&nfstatus=401&nftoken=00000000-0000-0000-0000-000000000000&nfstatusdescription=ERROR%3a+No+local+token
- Griffiths, D. M. (2004). Do tongue ties affect breastfeeding? *Journal of Human Lactation*, 20(4), 409–414.
- Haham, A., Marom, R., Mangel, L., Botzer, E., & Dollberg, S. (2014). Prevalence of breastfeeding difficulties in newborns with a lingual frenulum: A prospective cohort series. *Breastfeeding Medicine*, 9(9), 438–441.
- Hall, D. M., & Renfrew, M. J. (2005). Tongue tie. *Archives of Disease in Childhood*, 90, 1211–1215.
- Hazelbaker, A. K. (1993). *The assessment tool for lingual frenulum function (ATLFF): Use in a lactation consultant private practice* (Master's thesis). Pacific Oaks College, Pasadena, CA.
- Hazelbaker, A. K. (2010). *Tongue-tie: Morphogenesis, impact, assessment and treatment*. Columbus, OH: Aidan and Eva.
- Jones, M., & Prasaka, E. (2014). *Manual therapy prior to & after release of tethered oral tissues (commonly called tongue and lip ties)*. Retrieved from <http://www.musclesinharmony.com/manual-therapy-post-revisions.html>
- Kotlow, L. (2015). TOTS—tethered oral tissues: The assessment and diagnosis of the tongue and upper lip ties in breastfeeding. *Oral Health*, 64–70.

- Kupietzky, A., & Botzer, E. (2005). Ankyloglossia in the infant and young child: Clinical suggestions for diagnosis and management. *Pediatric Dentistry*, 27, 40–46.
- Masaitis, N., & Kaempf, J. (1996). Developing a frenotomy policy at one medical center: A case study approach. *Journal of Human Lactation*, 12(3), 229–232.
- McAndrew, F., Thompson, J., Fellows, L., Large, A., Speed, M., & Renfrew, M. (2012). *Infant feeding survey 2010: Summary*. Retrieved from hscic.gov.uk/catalogue/PUB08694
- Medeiros, A., Ferreira, J., & Felício, C. (2009). Correlations between feeding methods, non-nutritive sucking and orofacial behaviors. *Pro-Fono*, 21(4), 315–319.
- Meenakshi, S., & Jagannathan, N. (2014). Assessment of lingual frenulum lengths in skeletal malocclusion. *Journal of Clinical and Diagnostic Research*, 8(3), 202–204.
- Messner, A. H., Lalakea, M. L., Aby, J., Macmahon, J., & Bair, E. (2000). Ankyloglossia: Incidence and associated feeding difficulties. *Archives of Otolaryngology–Head & Neck Surgery*, 126(1), 36–39.
- Morgan, B. (n.d.) *What we have learned from our tongue tied babies*. Retrieved from <http://www.mobimotherhood.org/what-we-have-learned-from-our-tongue-tied-babies.html>
- Moss, W. (1794). *An essay on the management, nursing and diseases of children from the birth: and on the treatment of diseases of pregnant and lying-in women: With remarks on domestic practice of medicine* (2nd ed.). Egham, United Kingdom: Boulton & Longman.
- Praborini, A., Purnamasari, H., Munandar, A., & Wulandari, R. (2015). Early frenotomy improves breastfeeding outcomes for tongue-tied infants. *Clinical Lactation*, 6(1), 9–14.
- Ricke, L., Baker, N., Madlon-Kay, D., & DeFor, T. (2005). Newborn tongue-tie: Prevalence and effect on breast-feeding. *The Journal of the American Board of Family Practice*, 18(1), 1–7.
- Rowan-Legg, A. (2015). Ankyloglossia and breastfeeding. *Paediatrics & Child Health*, 20(4), 209–218.
- Simpson, J. (2015). *Structure and function*. <http://www.jayesimpson.com/structure-and-function/>
- Todd, D. (2014). Tongue-tie in the newborn: What, when, who and how? Exploring tongue-tie division. *Breastfeeding Review*, 22(2), 7–10.
- Todd, D., & Hogan, M. J. (2015). Tongue-tie in the newborn: Early diagnosis and division prevents poor breastfeeding outcomes. *Breastfeeding Review*, 23(1), 11–16.
- United Nations Children’s Emergency Fund. (2014). *Infant and young child feeding*. Retrieved from http://www.unicef.org/nutrition/index_breastfeeding.html
- The Upledger Institute. (2011). *Discover craniosacral therapy*. Retrieved from www.upledger.com/therapies
- Walls, A., Pierce, M., Wang, H., Steehler, A., Steehler, M., & Harley, E., Jr. (2014). Parental perception of speech and tongue mobility in three-year olds after neonatal frenotomy. *International Journal of Pediatric Otorhinolaryngology*, 78, 128–131.
- Wanveer, T. (2009, October). The tongue: How craniosacral therapy can help this important muscle. *Massage Magazine*. Retrieved from <http://massagemag.com/the-tog-ue-how-craniosacral-therapy-can-help-this-important-muscle-6274/>
- Watson Genna, C. (2002). Tongue-tie and breastfeeding. *Leaven*, 38(2), 27–29.
- Watson Genna, C. (2013). *Supporting sucking skills in breastfeeding infants* (2nd ed.). Burlington, MA: Jones and Bartlett.
- World Health Organization. (2015). *Infant and young child feeding*. Retrieved from <http://www.who.int/mediacentre/factsheets/fs342/en/>



Patricia Berg-Drazin is an Internationally Board Certified Lactation Consultant and a Certified CranioSacral Therapist, who provides a holistic approach to working with her patients. She received her IBCLC certification in 1990. She started studying with the Upledger Institute in 1997 and received her CranioSacral certification in 2010. Patricia sees patients primarily through her private practice, as this affords her the most flexibility in optimal care provision.

Patricia continually bolsters her knowledge base by attending and presenting at conferences around the world. She presents on topics ranging from engorgement to the etiology of structural issues that affect breastfeeding, as well as the importance of CranioSacral therapy in tongue-tied infants and children with challenges.

Patricia has authored a number of works, including: “Taking Nipple Shields out of the Closet,” “A Growth on the Nipple.” (a case study of staph infection on the nipple), and “Using a Mirror to Assist with Pumping.”

Patricia has two children, Michael and Richard.